

DISSECTION OF THE FETAL PIG

The period of gestation for pigs is 112- 115 days and each female may produce a litter of 7-12 . as development proceeds, the pig embryos get longer, so an approximate age can be calculated from the length. (from Odlaug: Laboratory Anatomy of the Fetal Pig. Wm. C. Brown, publ 1955.

11 mm 21 days
17 mm 35 days
2.8 cm 49 days
4.0 cm 56 days
22 cm 100 days
30 cm birth

COMPARED TO HUMAN LENGTH: from Blechschmidt: The Beginnings of Human Life. Springer Verlag, 1977.

1.6 mm 21 days
4-6 mm 28 days
7-12mm 37 days from 4-6 weeks, the embryos grow 22-24mm 52 days about 1
mm per day (crown-rump), 7 cm 3 lunar months and for the rest of gestation 12 cm
4 1-1.5 mm a day except in the 17 cm 5 fourth month, it is 2 mm/day.
21 cm 6 The increase in weight is six 24.5 7 billion times.
28.5 8
32 9
33.5 10

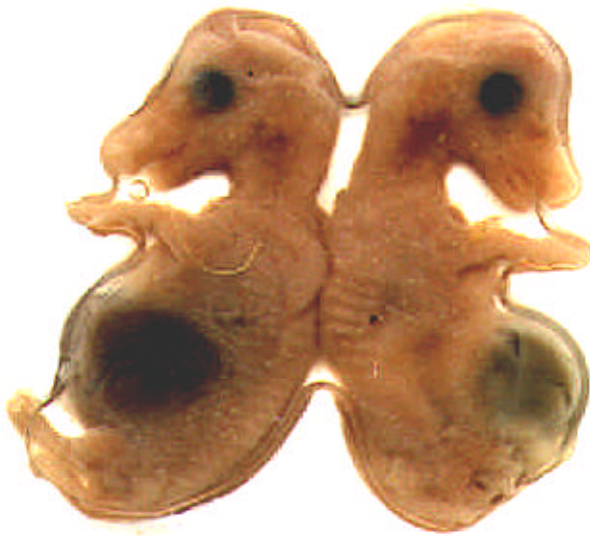We have collections of about ten different sizes of pig embryos and fetuses and many human embryos and fetuses.

EXTERNAL APPEARANCE There are two measurements used to arrive at these numbers and the age of the embryo or fetus: crown-rump length and the degree of cervical flexion. Then the crown-heel length is the one used for older fetuses in humans and at the time of birth (but crown-rump was used in the chart above.)

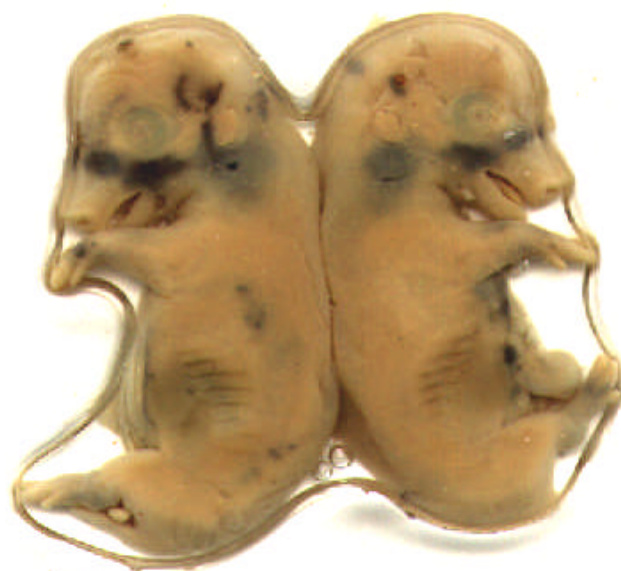

28mm

32



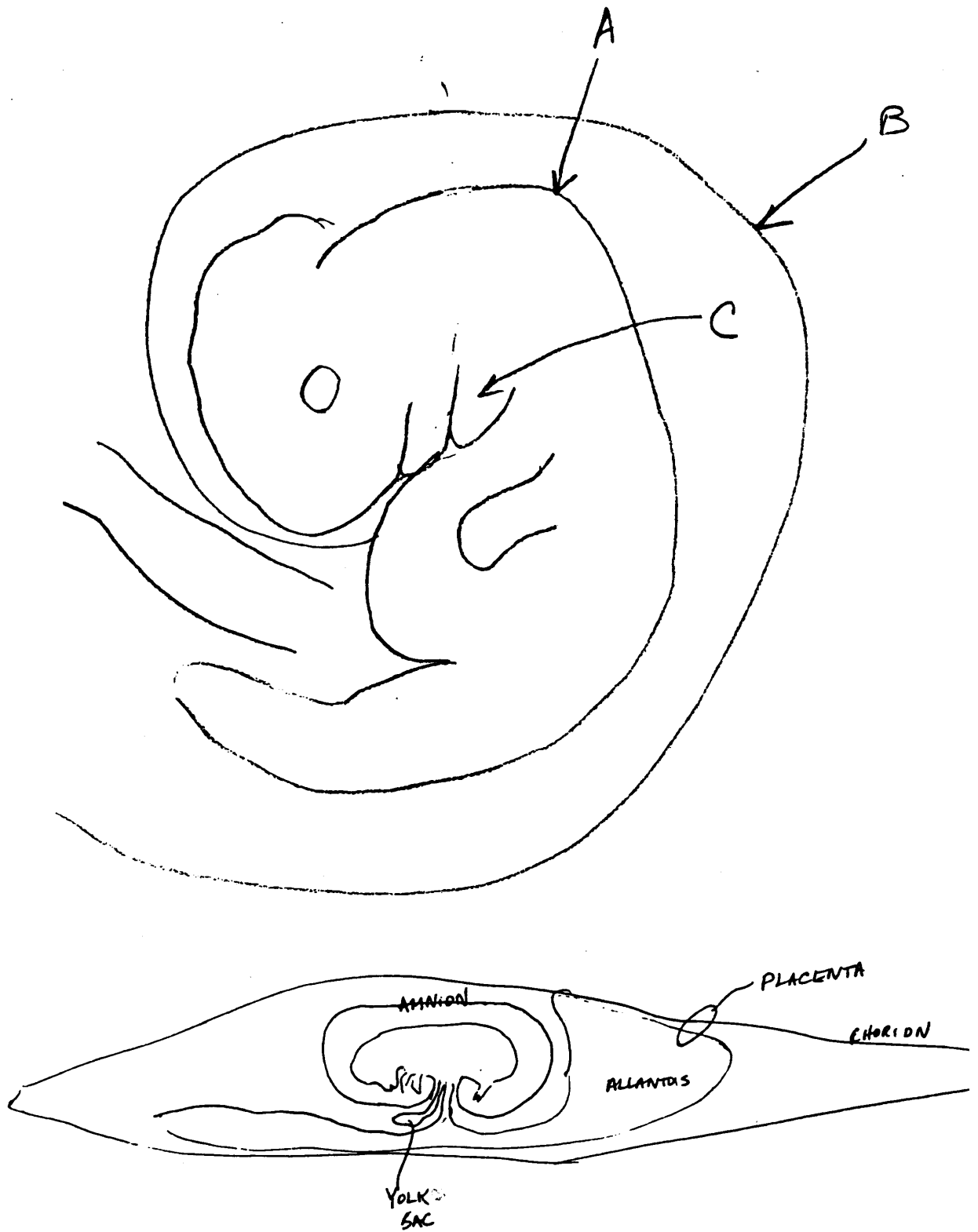
mm



36mm



42 mm



In study of each embryo, fill in the table on the attached sheet, answering the questions about each

embryo. First measure the crown-rump length, then the angle of cervical flexion, using a compass, provided by the instructor.

Next look at the appearance of the obvious structures: 1. ears, are the external ears present? Is there a shape change in the older pigs? 2. eyes, are there eyelids, are they closed, and are the nictitating membranes present? 3. nostrils, are they complete and separate from the upper lip? 4. mouth, are the lips completed? see your lab book about development of the human face, palate, 5. limbs, are the joints at the elbows, wrists, ankles, knees present and are the digits and hooves present? 6. tail, describe the shape and stiffness, 7. muscle masses, are there obvious somites or segments down the back? Are there ribs in the thorax or upper trunk? 8. genitalia, is it male or female? males have scrotal sacs under the tail and urogenital (UG) openings near the umbilical cord whereas females have UG openings right underneath the anus (right under the tail) with a genital papilla in it, 9. hair, distribution of follicles, 10. mammary glands, both sexes have them along the abdomen, in rows of 5-7, 11. umbilical cord, in cross section you can see two large thick walled arteries which carry unoxygenated blood to the placenta and one vein which carries oxygenated blood to the fetal heart from the placenta.

Examine the preparation of the fetus with fetal membranes: measure the length of the whole placenta. Can you see the folds on its surface which interdigitate with folds of the uterus)? There are no villi on pig chorion which correspond to those on the disc of the human placenta. The connection with the mother is much less intimate, so there is little bleeding at birth of pigs. In order to see these folds, use the dissection microscope. Examine the fetal pig in the jar which has an injected placenta, with arteries in red and veins in blue. Compare it to placentas of sheep, cat, other mammals shown mounted in jars and to the human placentas we have seen.

Next, cut open the fetal membranes (the chorion vesicle is outermost) carefully so you can keep them, **BEING CAREFUL NOT TO CUT A SECOND MEMBRANE INSIDE**, then examine the connection of the umbilical cord with the membranes and see if you can tell the difference between the allantois, (which is fused with the chorion and is used to store urine in pig development, and to bring the circulation to the uterine lining to get oxygen and release wastes) and the amnion, which contains the fluid which protects the embryo from drying and mechanical injury, and the outer chorion, and yolk sac.

Look at the slide of human placenta villi. The round or irregularly shaped structures are sections of the villi. Each villus after the fourth month has: 1. a blood vessel in it which will probably contain blood cells. 2. Around the blood vessel is connective tissue which contains a few cells and a lot of extracellular material which is fibers and matrix material. 3. Around the connective tissue is the syncytiotrophoblast (syntrophoblast) which separates the mother's blood from the rest of the villus, since the mother's blood is in the 4. intervillous space or lacuna between the villi. **MAKE A DRAWING LABELING THESE FOUR STRUCTURES.**

FETAL PIG COMPARISON OF EXTERNAL ANATOMY

NAME-----

FILL IN THE BLANKS IN THE FOLLOWING TABLE AFTER EXAMINING THE FETAL PIGS

FIG 1	FIG2	FIG3	FIG4	FIG5	FIG6	FIG7	FIG8	LENGTH
_____ANGLE OF								
CERV. FLEXION_____						NOSTRILS		

- EYES
- LIDS
- EARS
- LIMBS
- KNEES
- ANKLES
- DIGITS
- HOOFS
- SOMITES
- TAIL
- MAMMARY
- GENITALS
- PAPILLA
- SCROTAL SAC
- UG OPENING
- HAIR

WHAT IS DIFFERENT ABOUT THE PIG PLACENTA AS COMPARED TO HUMAN, CAT, OTHER MAMMALS?

WHAT IS DIFFERENT ABOUT THE CHORION, ALLANTOIS, YOLK SAC, AND AMNION? HOW CAN YOU TELL THEM APART? WHAT IS THE RELATIONSHIP OF THE UMBILICAL CORD TO THEM?

DRAW THE HUMAN PLACENTA SECTION, SHOWING VILLI AND RELATED STRUCTURES.