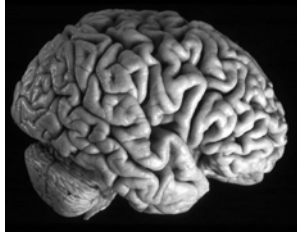


**Evaluation
of the
Head
&
C-Spine**



HISTORY

*Things are a little
different
this time
around!*



History

- Loss of consciousness
- Amnesia
 - Retrograde
 - Anterograde
- Self-reported symptoms
 - Headache
 - Tinnitus
 - Nausea
 - Vision
- Previous history of concussion

Multiple concussion patterns

- From lighter impacts
- Closer together in time
- Lengthier recovery
- Less complete recovery

*Catastrophic head and neck injury **must** be ruled out before proceeding with a "normal" evaluation!!!*

OBSERVATION

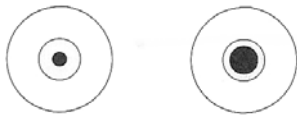Lots to pay attention to!



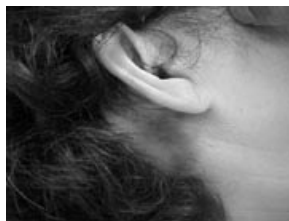Observation / Inspection

- Position of head
- Position of neck
- Skull and scalp
- Athlete behavior

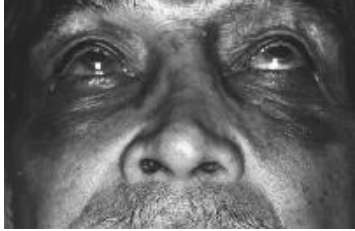Pupils - PEARL



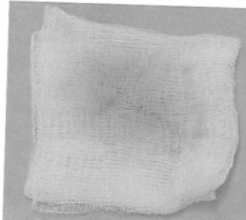
Battle's Sign



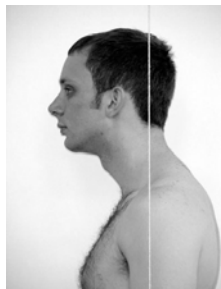
Raccoon Eyes



Ears – Blood or CSF



Posture



PALPATION

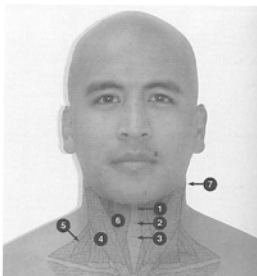
*Rule out skull and
C-spine fractures!!*



Bony Landmarks

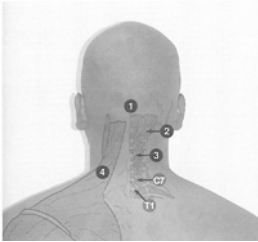
C1 TP	One finger inferior to mastoid process
C3-C4	Posterior to hyoid bone
C4-C5	Posterior to thyroid cartilage
C6	Posterior to cricoid cartilage
T1	Prominent spinous process

Palpations – Anterior



1. Hyoid Bone
2. Thyroid Cartilage
3. Cricoid Cartilage
4. SCM
5. Scalenes
6. Carotid Artery
7. Lymph Nodes

Palpations – Posterior



1. Occiput & Superior Nuchal Line
2. TPs
3. SPs
4. Trapezius

STRESS

- Nerve
- Vascular
- Bone
- Joint
- Muscle / Tendon

Nerve Testing

- Brain
- Cranial Nerves
- Upper and Lower Motor Neurons
- Cervical Nerve Roots & Brachial Plexus

Brain

- Memory *Every 5 minutes...*
- Cognitive *...and few days...*
...and after exertion!
- Balance and Coordination
- Vital Signs

*Compare to baseline
measures.*



Balance and Coordination

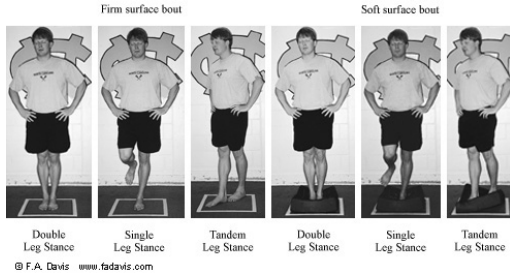


© F.A. Davis www.fadavis.com



© F.A. Davis www.fadavis.com

Balance Error Scoring System

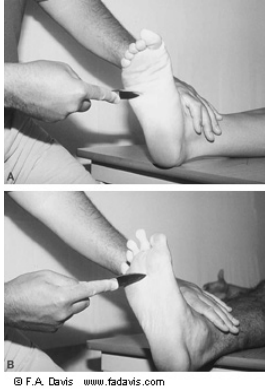

Cranial Nerve Function

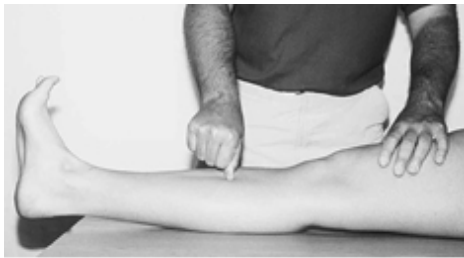I	Smell	VII	Expressions
II	Vision	VIII	Hearing
III	Rx to light	IX	Swallow
IV	Eyes up	X	Swallow
V	Clench jaw	XI	Shoulder Shrug
VI	Eyes lateral	XII	Stick out tongue

Upper Motor Neurons

Babinski Reflex



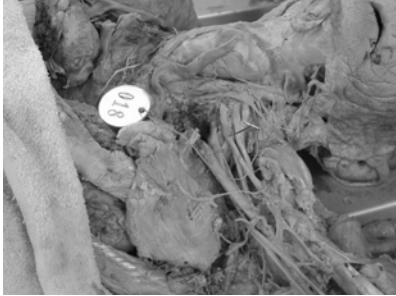Oppenheim Test



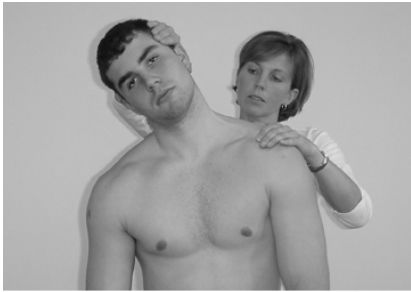Lower Motor Neurons

- Upper Quarter Screen
- Lower Quarter Screen

Cervical Nerve Root & Brachial Plexus




Brachial Plexus Traction Test




© F.A. Davis www.fadavis.com

Shoulder Abduction Test

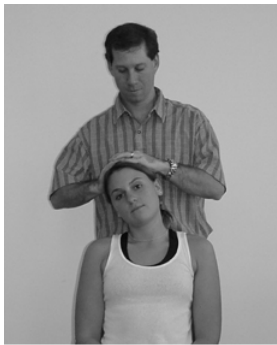


Cervical
Compression
Test



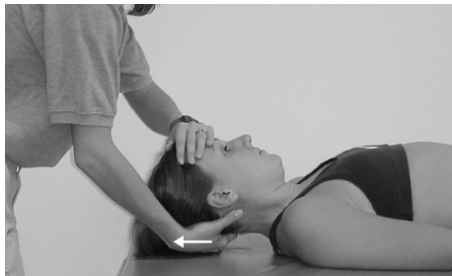
© F.A. Davis www.fadavis.com

Spurling
Test



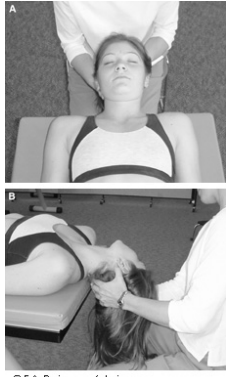
© F.A. Davis www.fadavis.com

Cervical Distraction Test



© F.A. Davis www.fadavis.com

Vertebral Artery Test

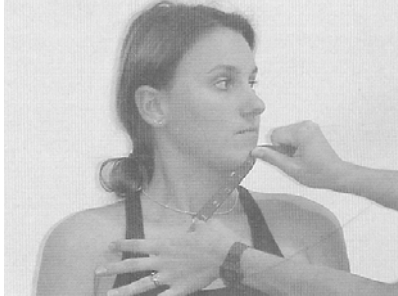

Bone?

Joint

- Spring Test
- Passive ROM

Range of Motion



Cervical and Capital ROM

- Flexion
- Extension
- Lateral Bending
- Rotation

Muscle / Tendon

- Resisted ROM
