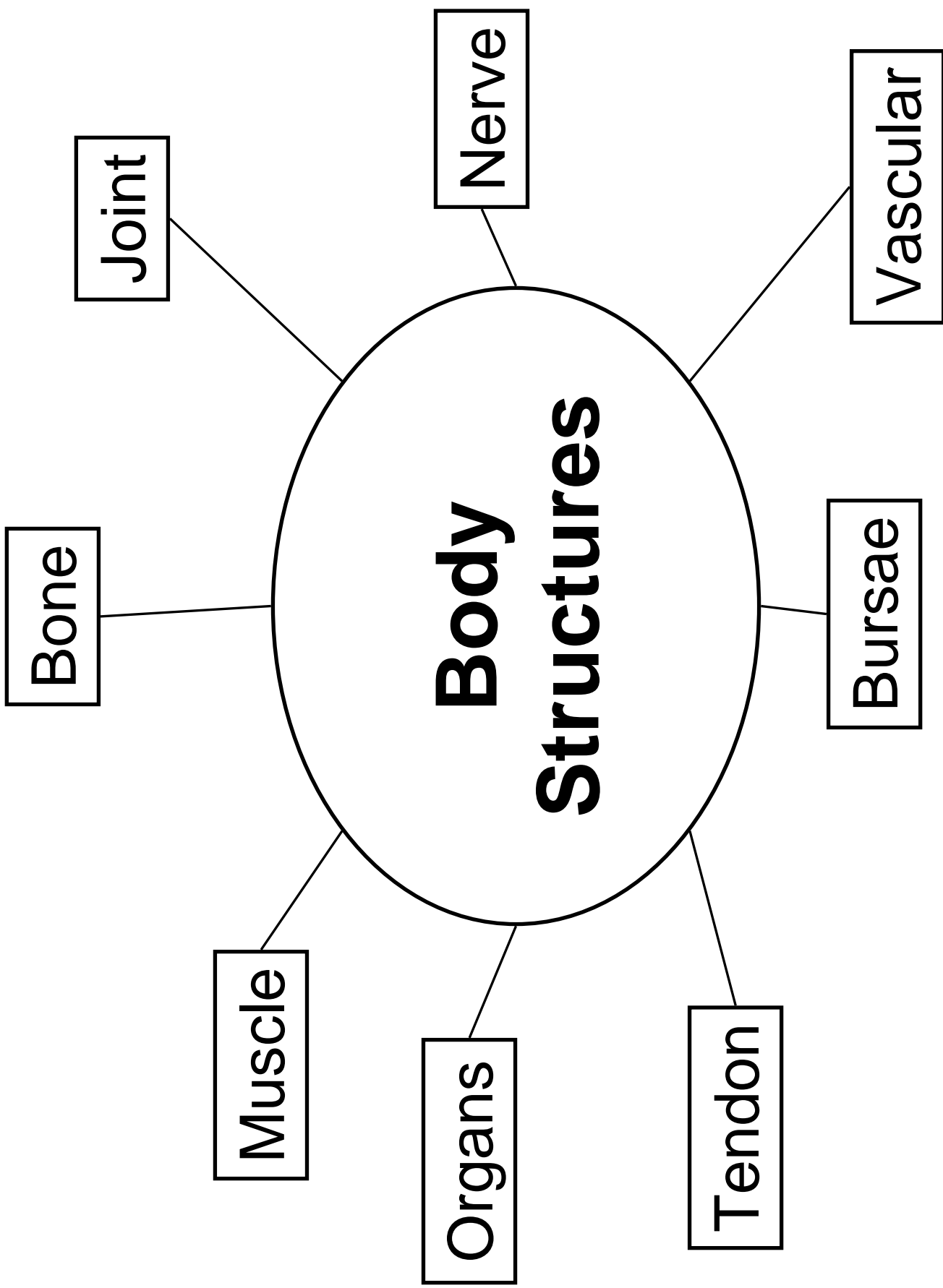


Kinesiology 338/L  
Lower Extremity Evaluations

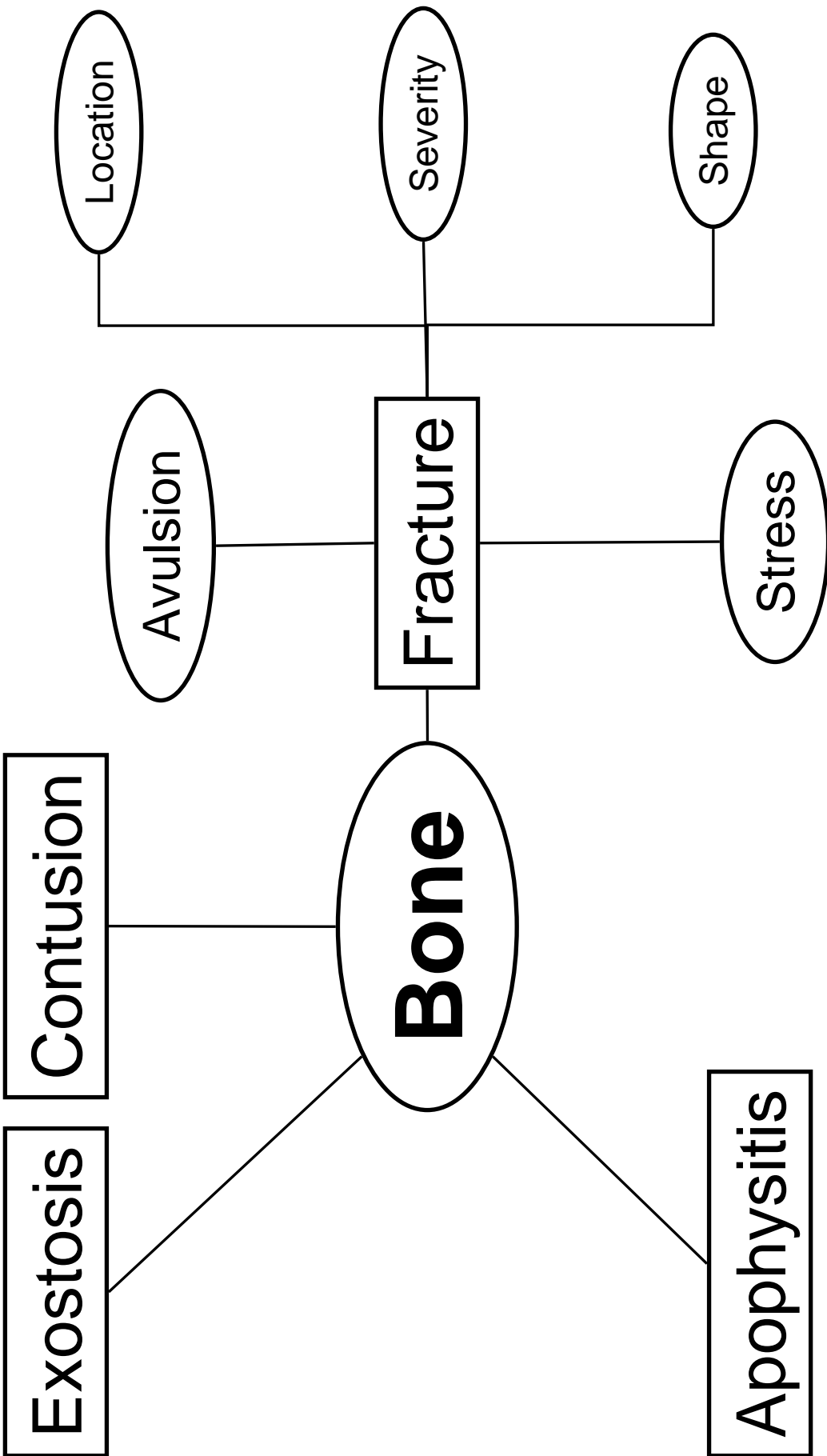
---

**Sean P. Flanagan, PhD, ATC, CSCS**  
**Department of Kinesiology**  
**California State University, Northridge**

# Introduction



Classification



# **FRACTURE CLASSIFICATIONS**

## A. By Location

1)

2)

3)

## B. Severity

1)

2)

3)

4)

## C. Shape

1)

2)

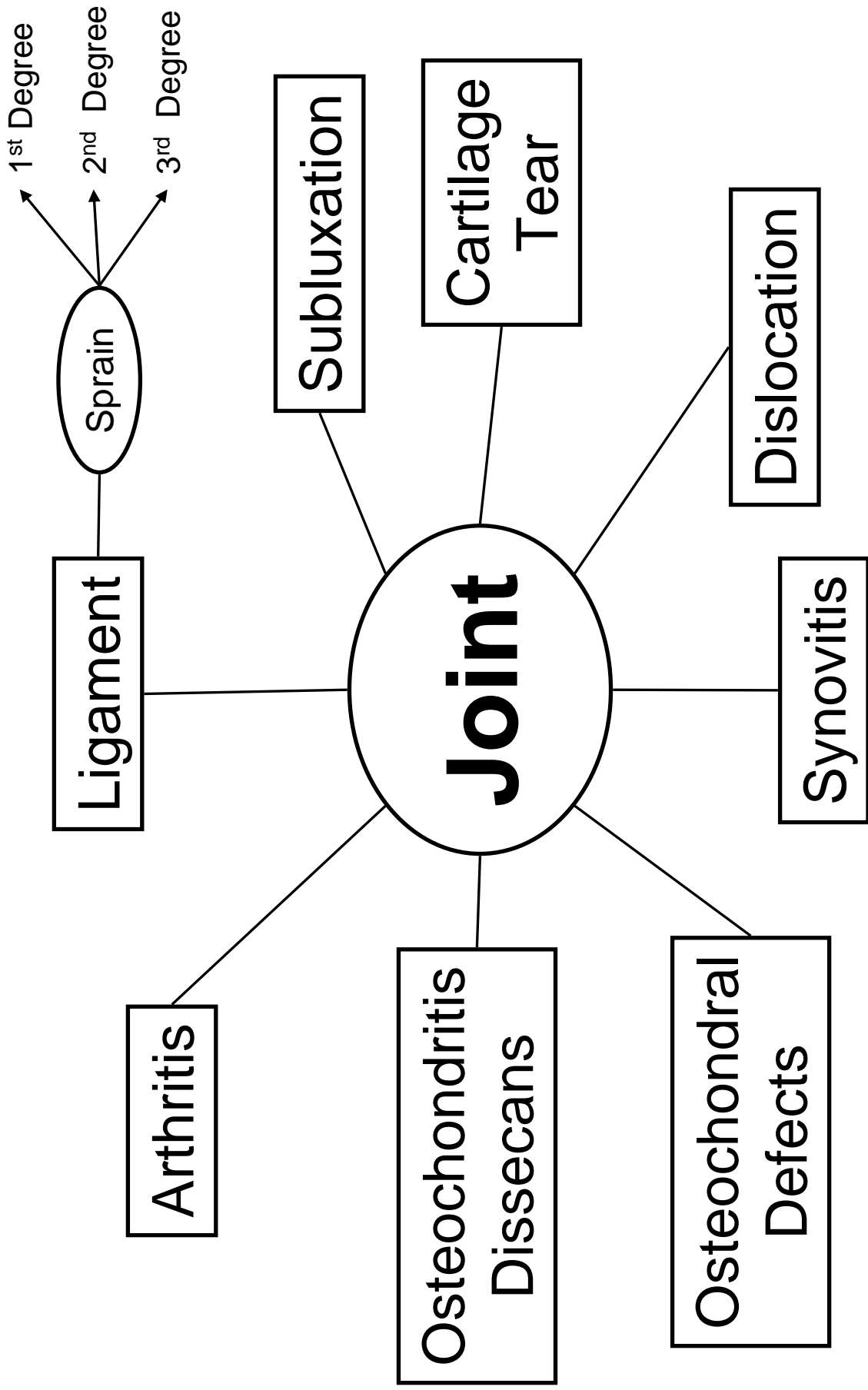
3)

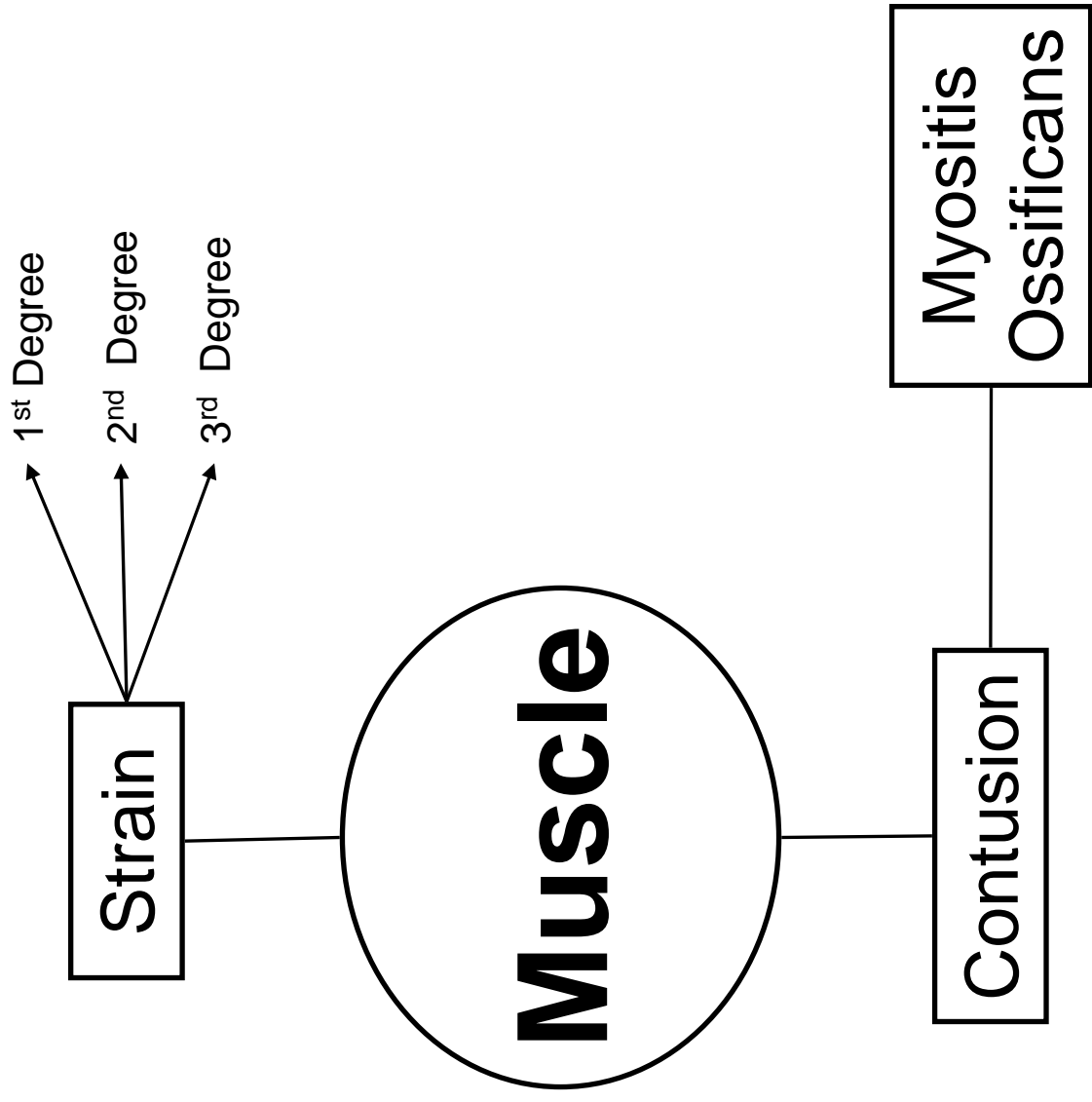
4)

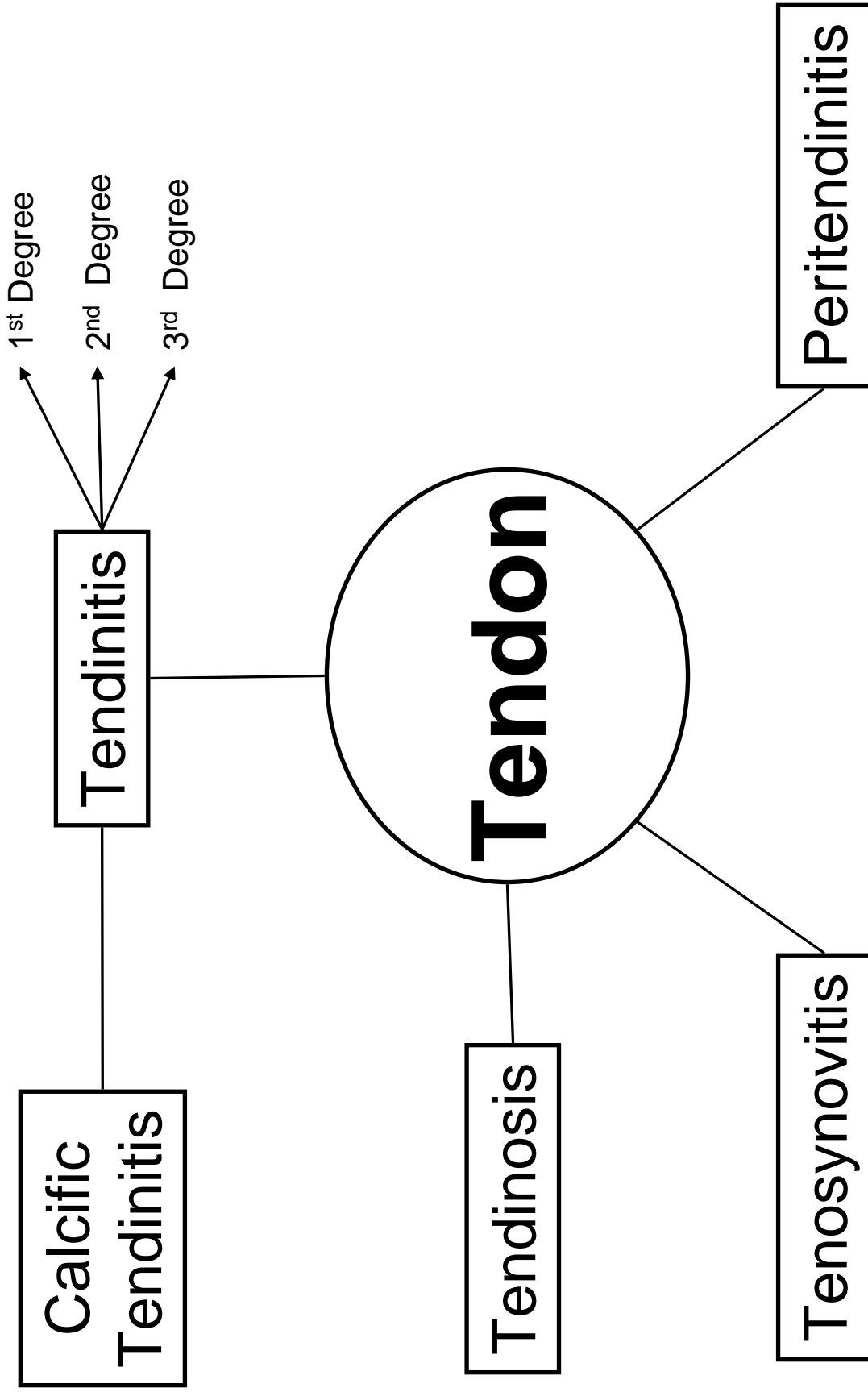
5)

6)

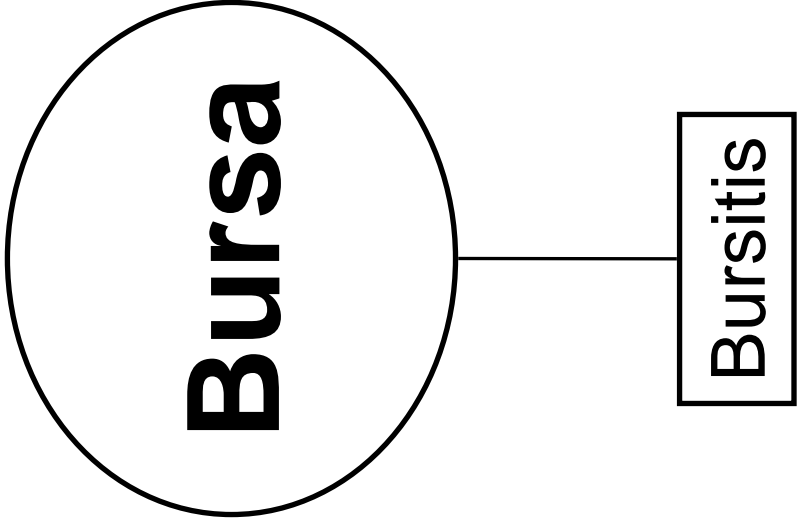
7)

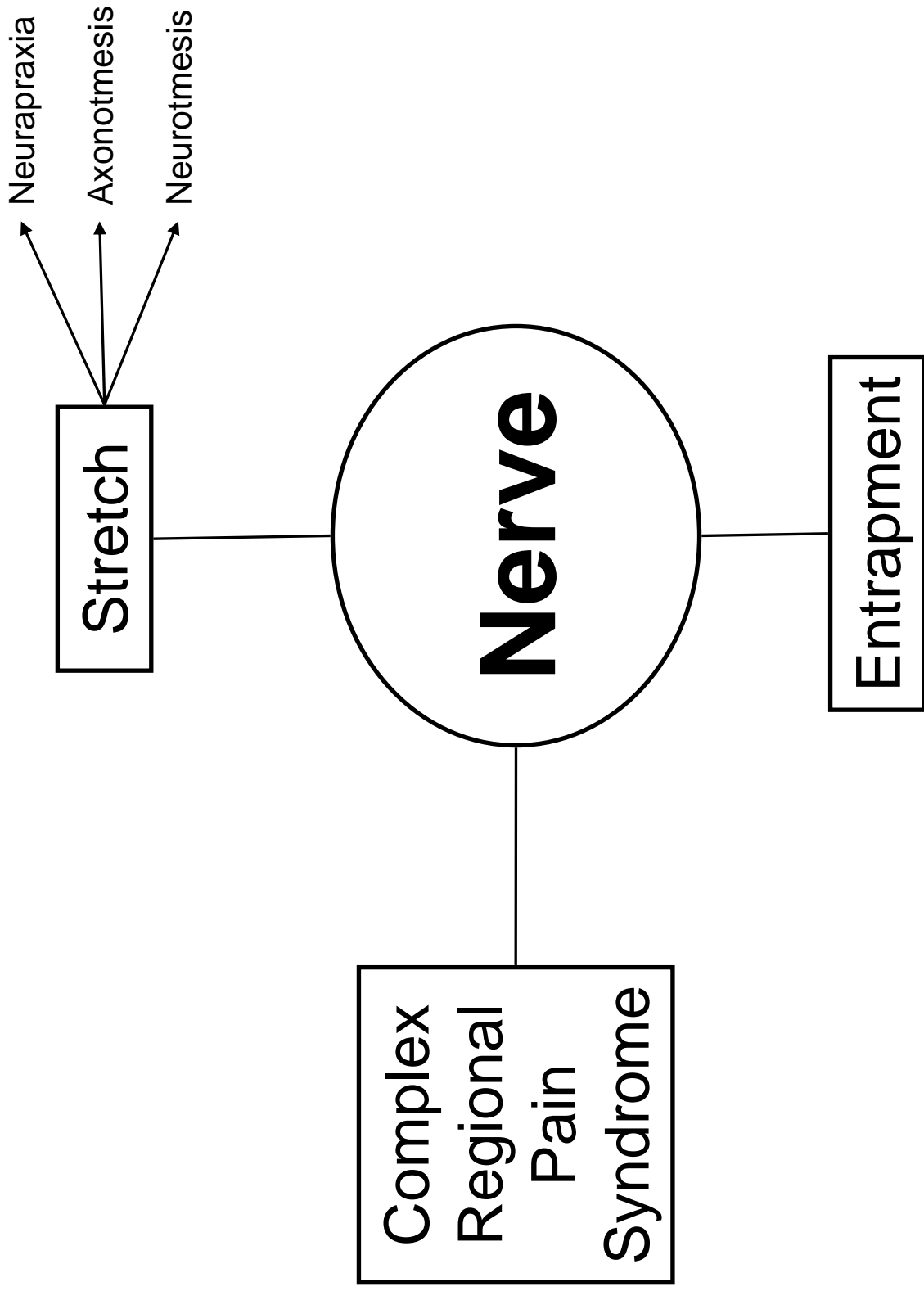













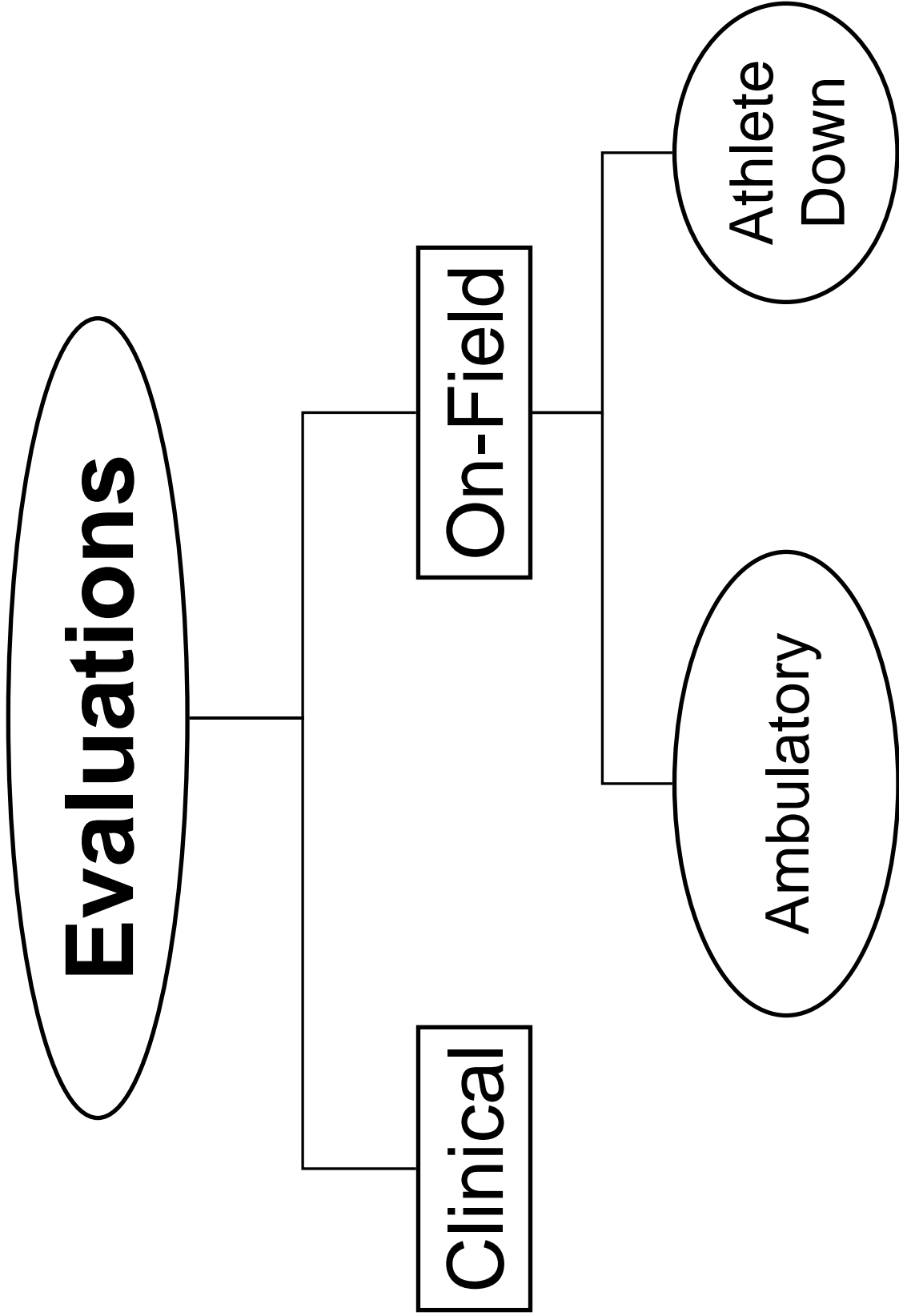
## COMPARING TISSUE INJURIES

Structure	Nomenclature	Description
Ligament		
Muscle		
Tendon		
Nerve		



**Vascular**

# Injury Evaluation Principles



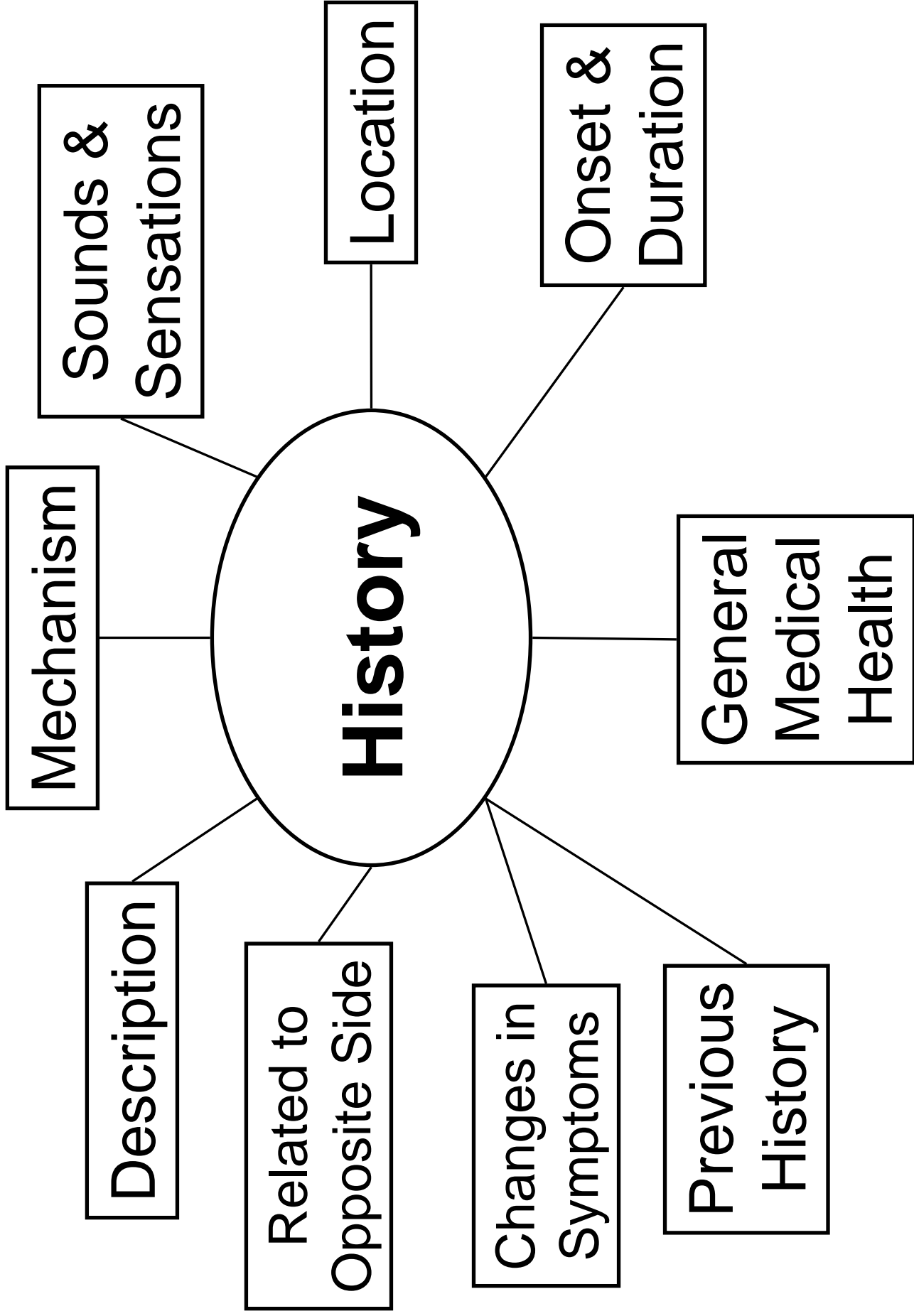
# Injury Evaluation Process

H

O

P

S





## **COMMON DESCRIPTIONS OF PAIN**

A.BONE

B.FRACTURE

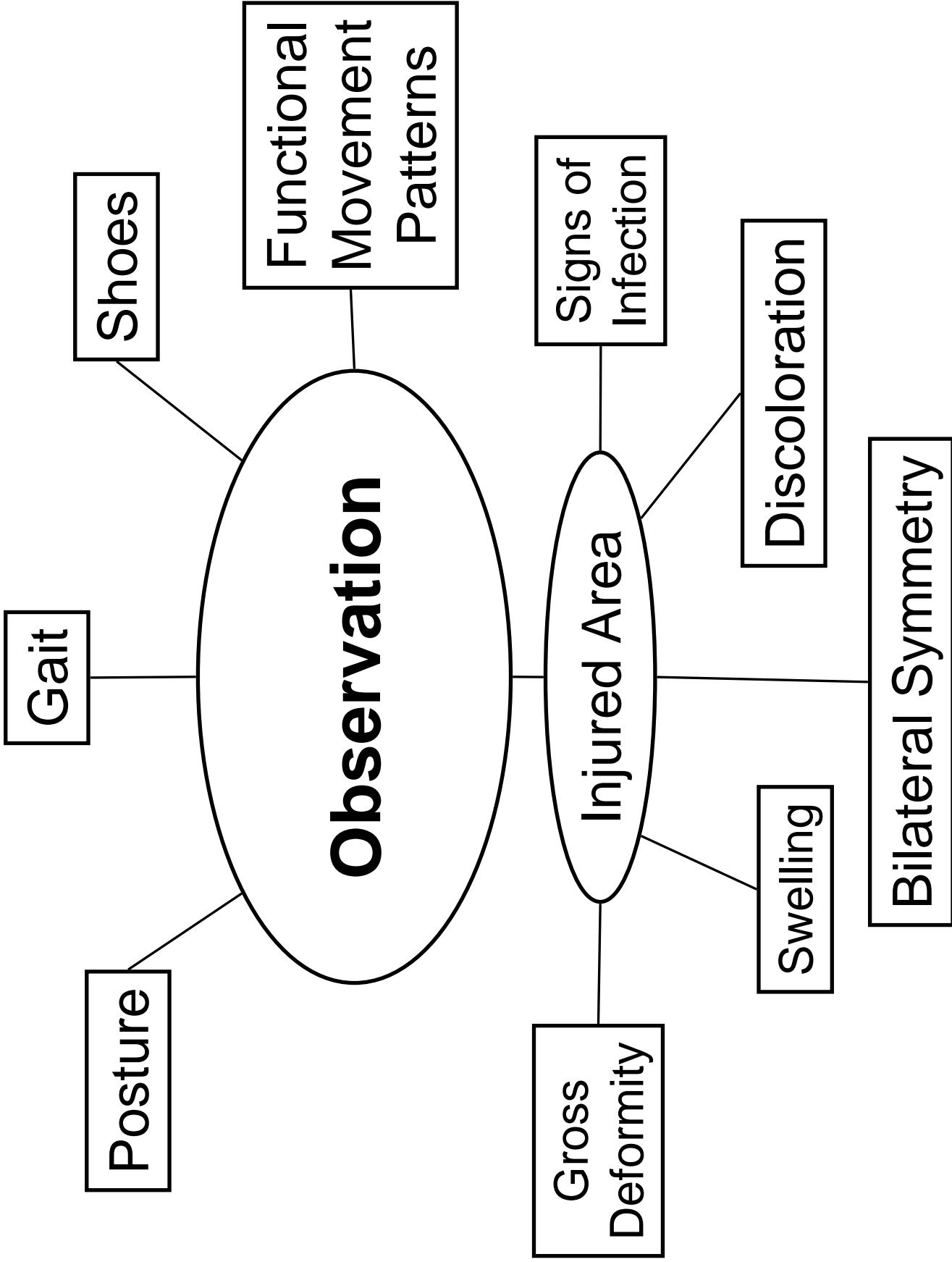
C.JOINT

D.MUSCLE / TENDON

E. BURSAE

F. NERVE

G.VASCULAR



## **SIGNS OF INFECTION**

A. Pain

B. Redness

C. Swelling

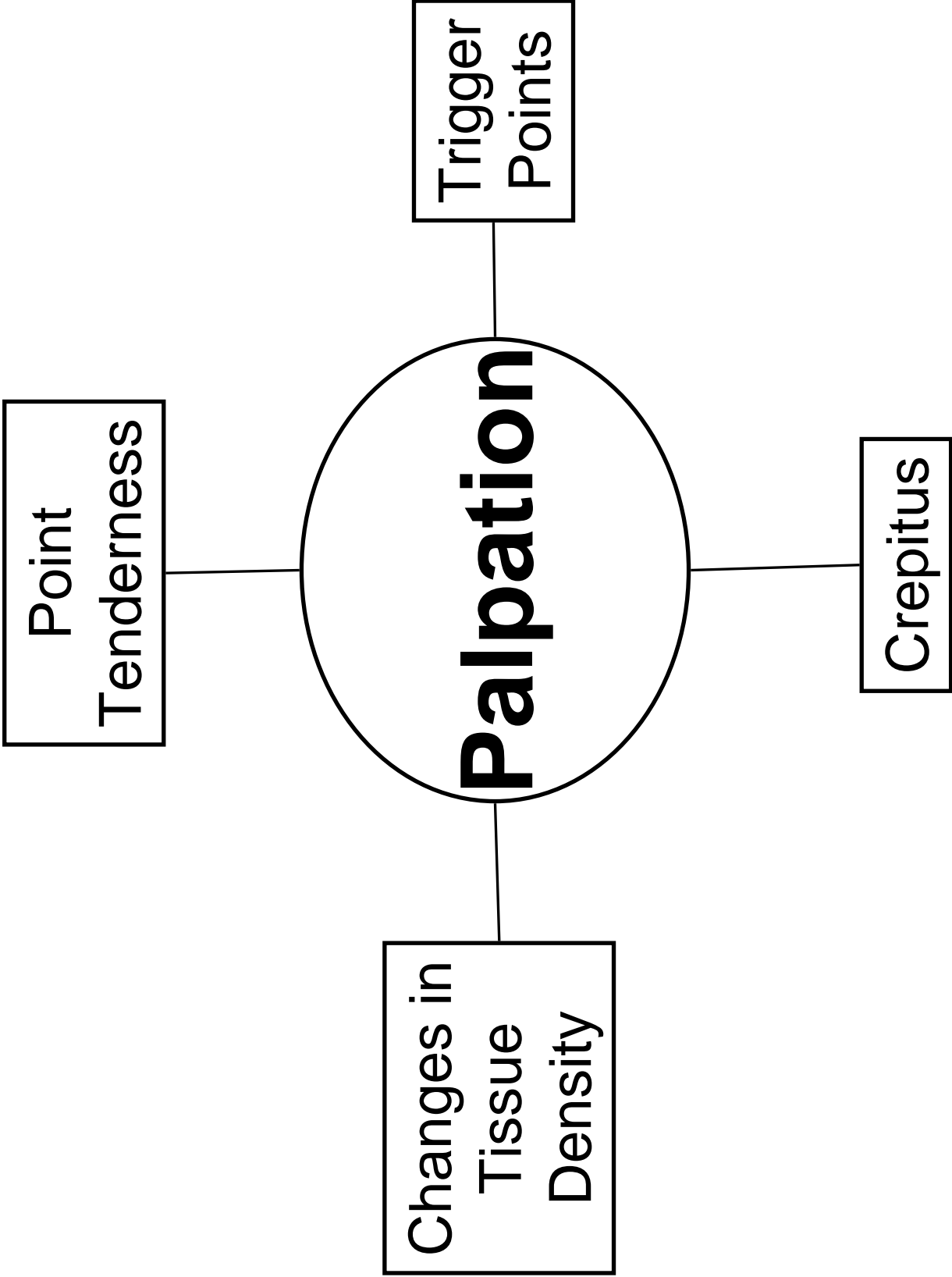
D. Pus

E. Foul Odor Drainage

F. Heat to Site

G. Fever

H. Swollen Lymph Nodes



# **PALPATION GUIDELINES**

A. Practice Self Palpation

B. Less is More

C. Movement vs. Stillness

D. Develop a Sequence

1) Structures

2) Areas

E. Begin on Opposite Side / Away from Pain

# Stress Tests

**Bone**

**Joint**

**Muscle /Tendon**


**Bursa**

**Nerve**

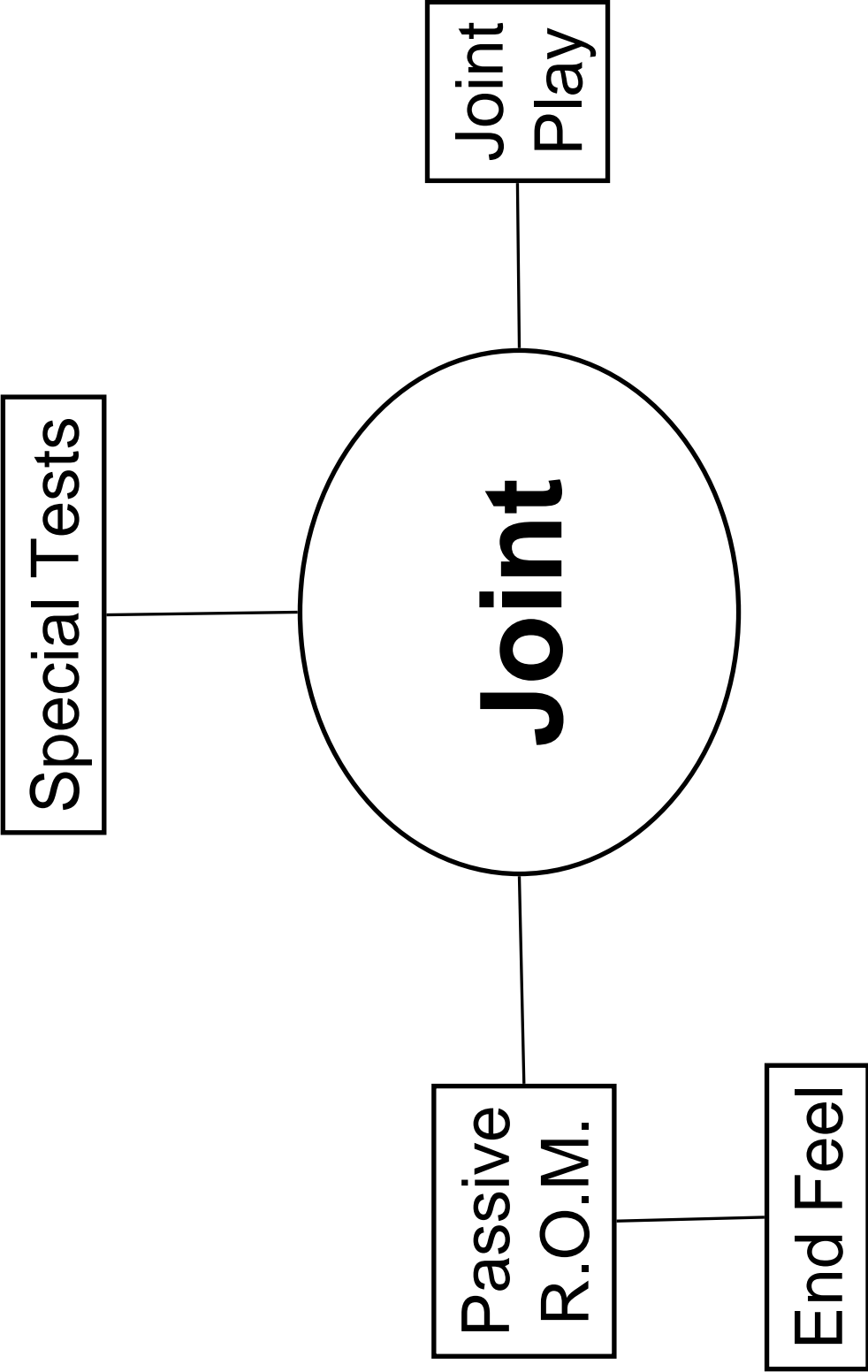
**Vascular**

**Organs**

Long Bone  
Compression



Percussion





# **END FEELS**

## A. Normal

1)

2)

3)

## B. Abnormal

1)

2)

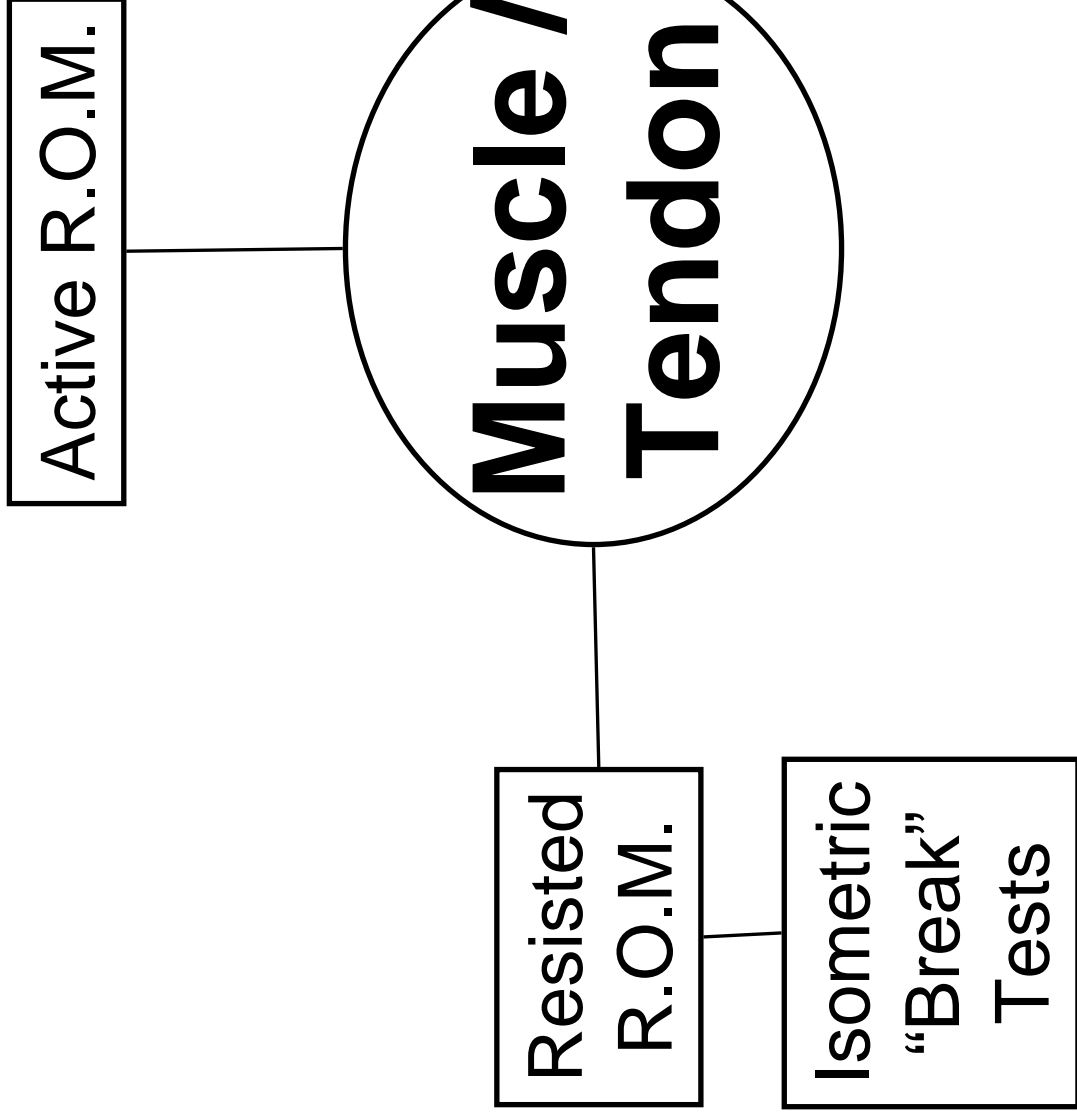
3)

4)

5)

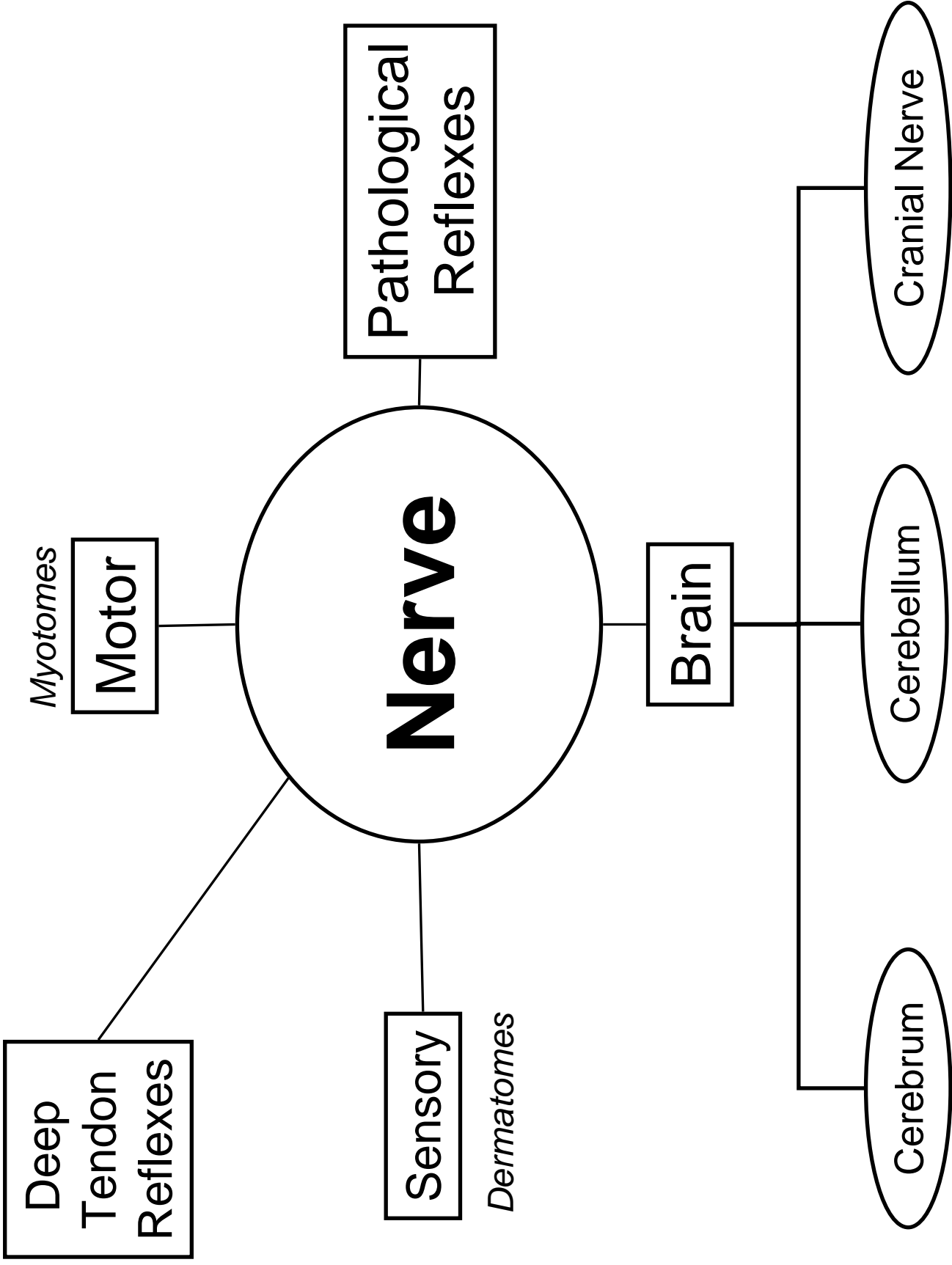
## GONIOMETRY – SFTR METHOD

Plane	1 <sup>st</sup> Number	2 <sup>nd</sup> Number	3 <sup>rd</sup> Number
Sagittal (S)			
Frontal (F)			
Transverse (T)			
Rotation (R)			
Hypomobility			
Fixed Joint Ankylosis			



## MUSCLE TEST GRADING

GRADE	VALUE	MOVEMENT



## **DEEP TENDON REFLEX GRADING**

GRADE	VALUE	PATHOLOGY


**Vascular**

Distal  
Pulses



X-Ray

Bone Scan



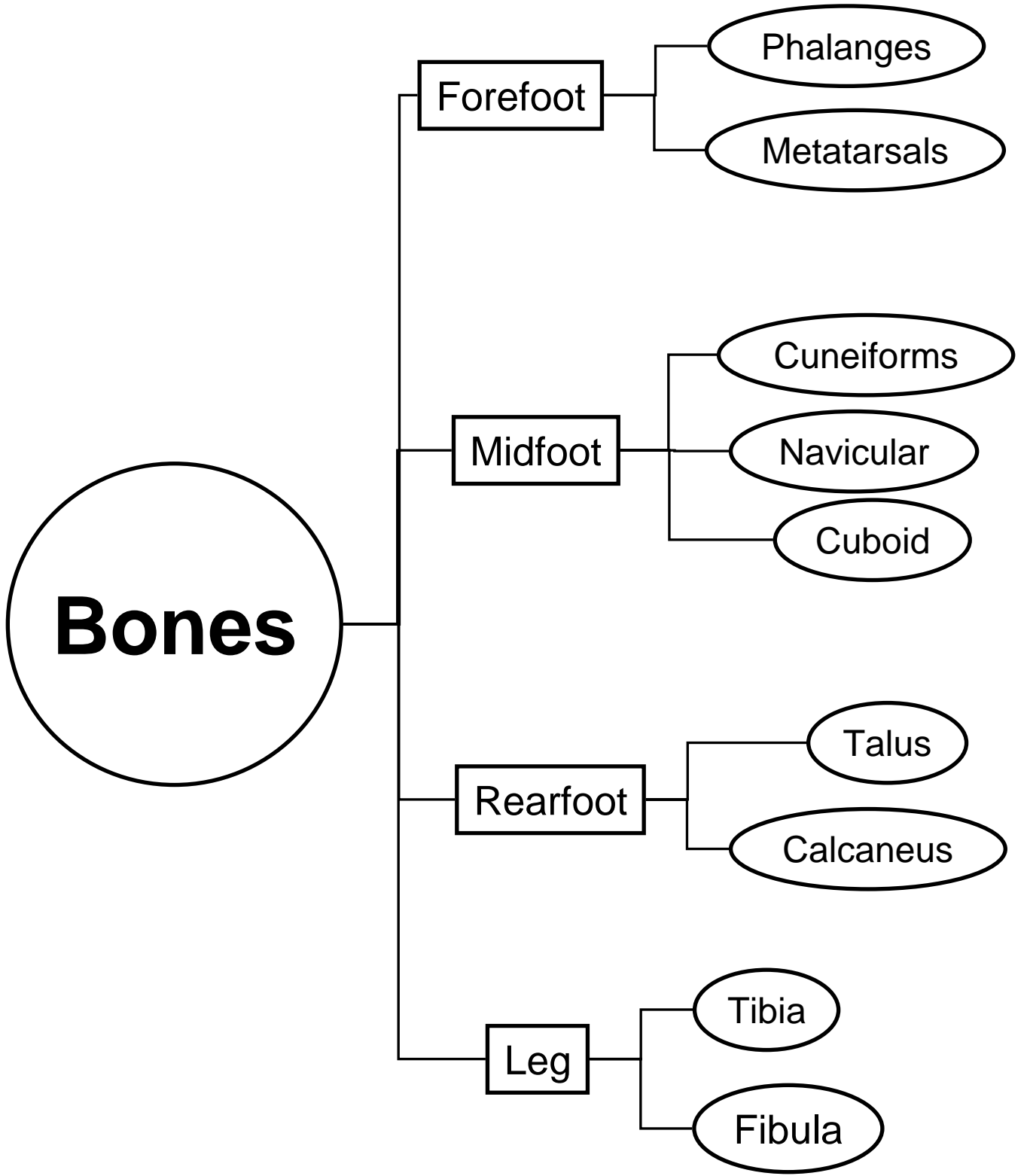
Ultrasound

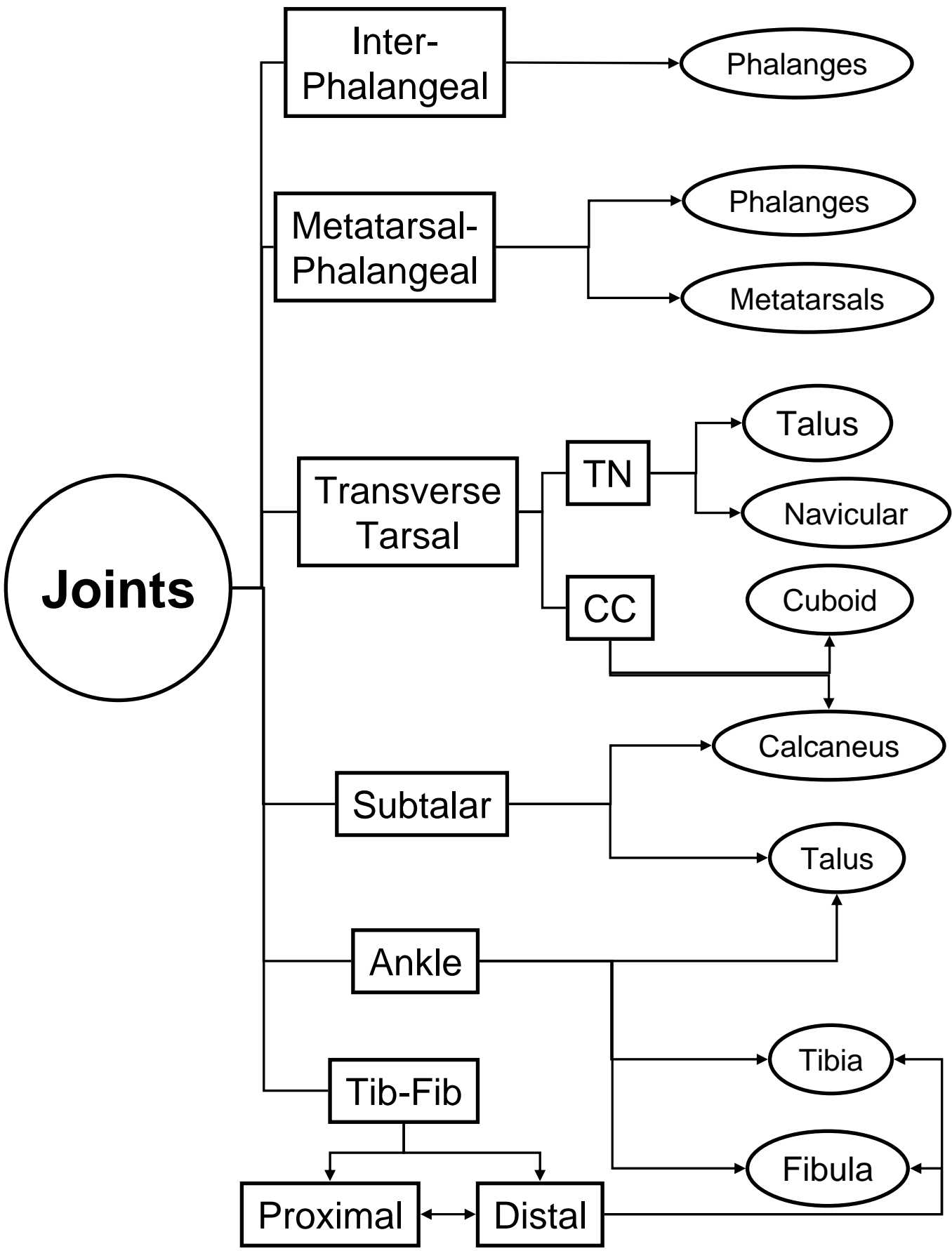
Magnetic  
Resonance  
Imaging

Computed  
Tomography



Foot, Toes,  
Ankle &  
Lower Leg





# Ligaments

Ligament	Connects	Restrains
Spring		
ATF		
CF		
PTF		
Deltoid		
Proximal Tib-Fib		
Distal Tib-Fib		

# Joint Motion

	Plane of Motion		
Joint	Sagittal	Frontal	Transverse
IP			
MTP			
Subtalar			
Ankle			

# Pronation & Supination

	Weight Bearing	Non-Weight Bearing
Pronation	Calcaneus	Calcaneus
	Talus	Calcaneus
	Talus	Calcaneus
Supination	Calcaneus	Calcaneus
	Talus	Calcaneus
	Talus	Calcaneus

# Muscle – Joint Interaction

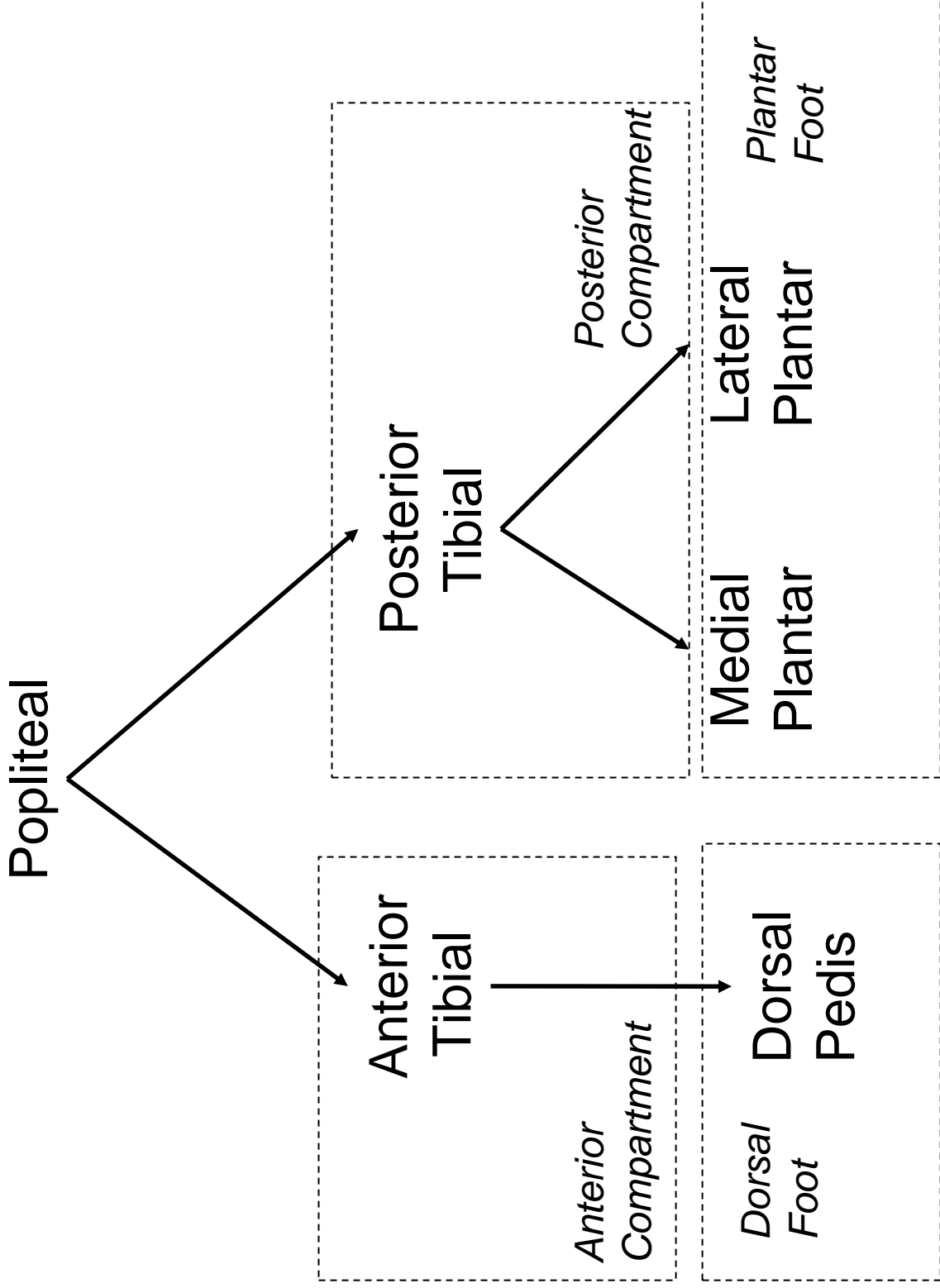
Motion	Prime Mover(s)
IP Flexion	
IP Extension	
MTP Flexion	
MTP Extension	
MTP Abduction	
MTP Adduction	

# Muscle – Joint Interaction

Motion	Prime Mover(s)
Rearfoot Inversion	
Rearfoot Eversion	
Ankle Dorsiflexion	
Ankle Plantarflexion	



# Blood Supply



# Nerve Supply

Sciatic

Common  
Peroneal

Deep  
Peroneal

Superficial  
Peroneal

Tibial

*Anterior  
Compartment*

*Dorsal  
Foot*

*Lateral  
Compartment*

*Posterior  
Compartment*

Medial  
Plantar

Lateral  
Plantar

*Plantar  
Foot*

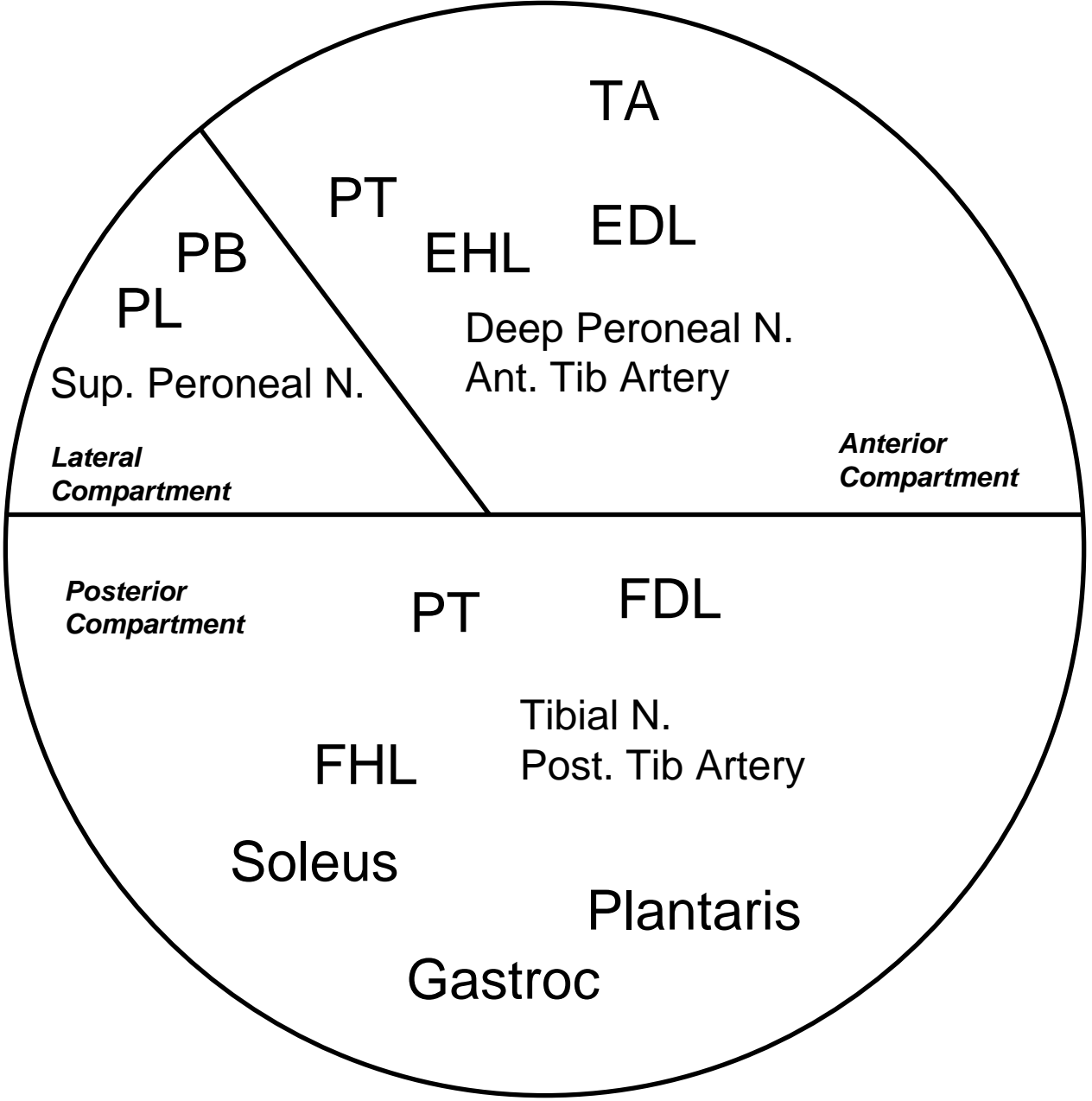
# Passing the Medial Malleolus

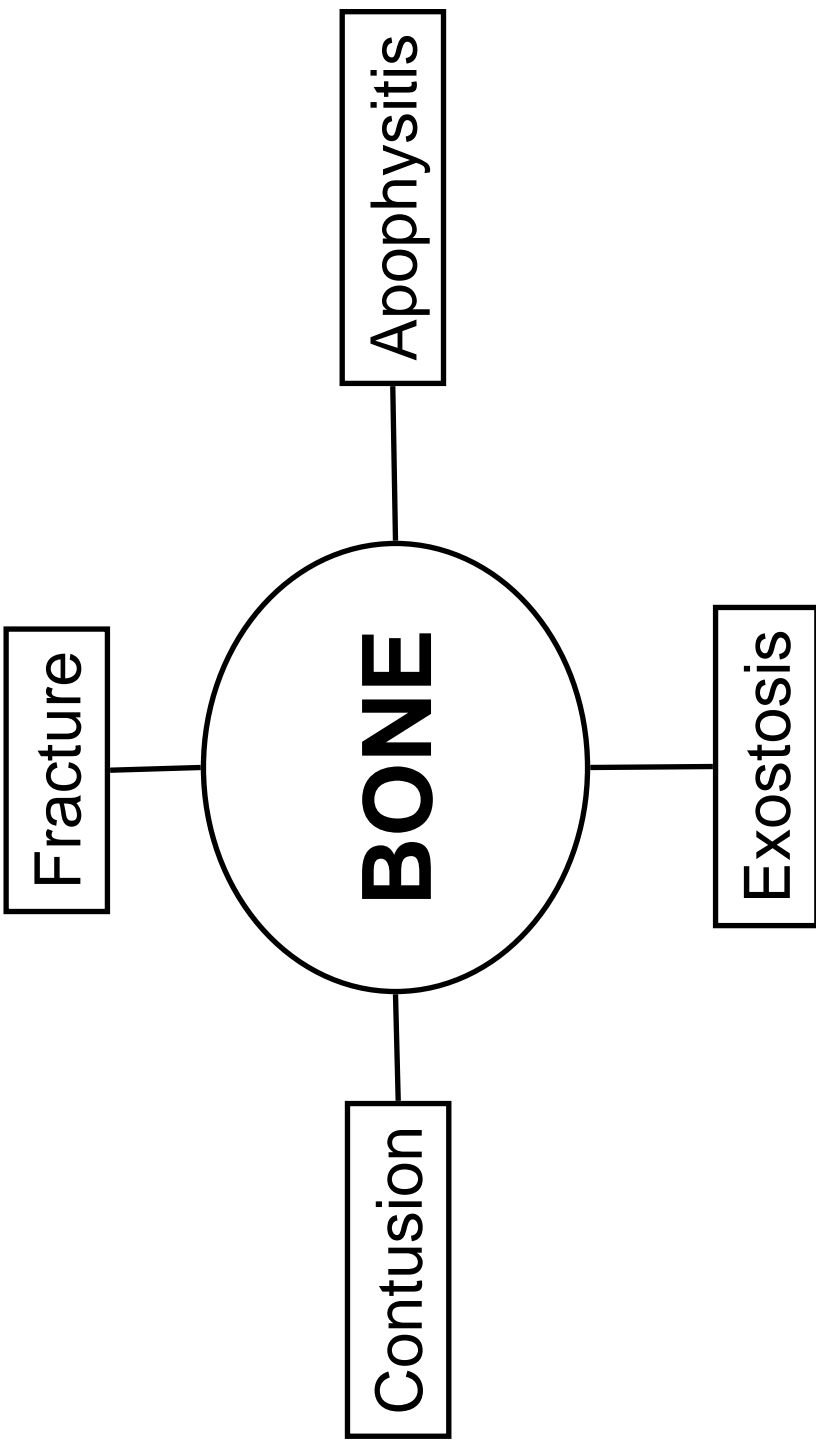
Tom

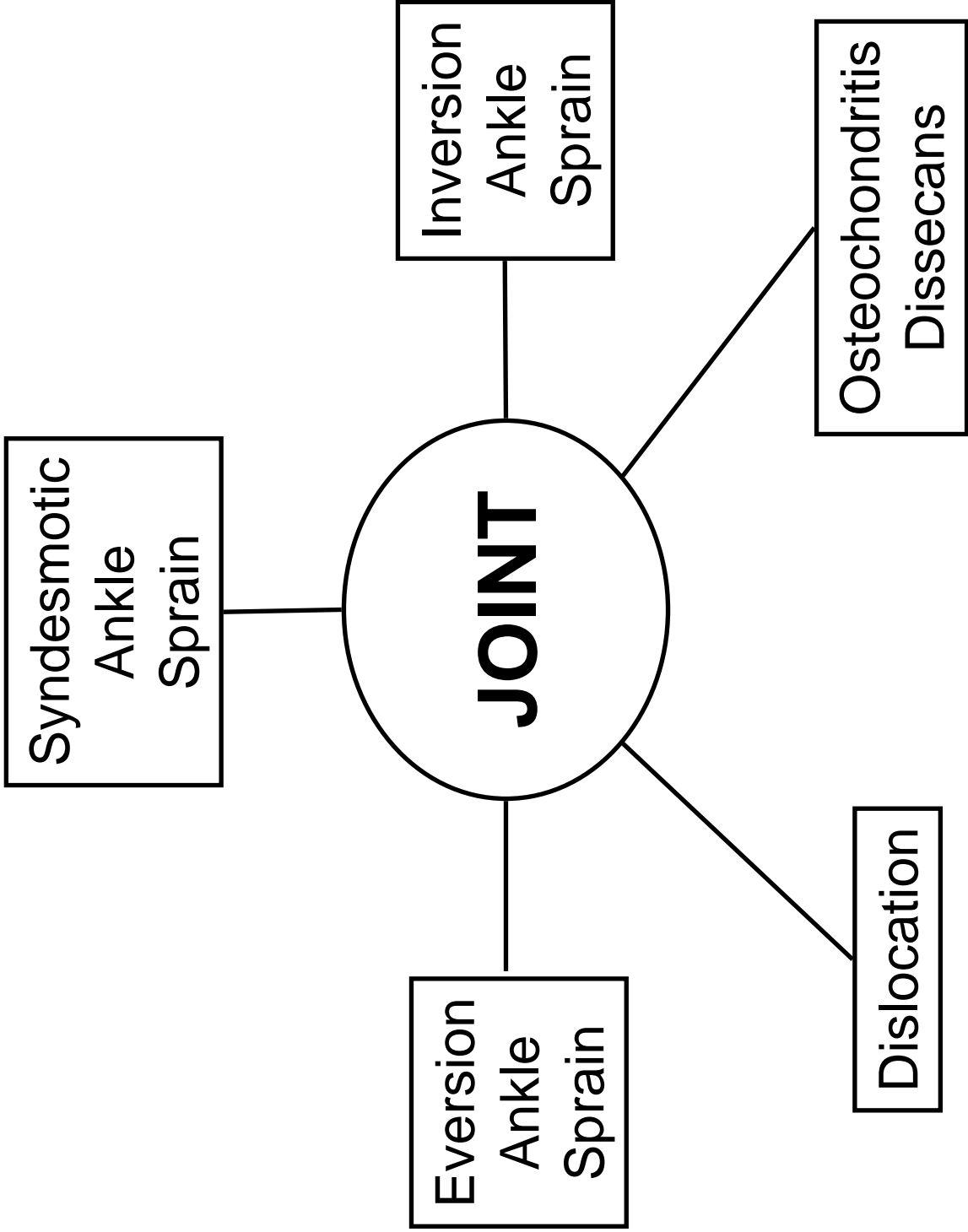
Dick

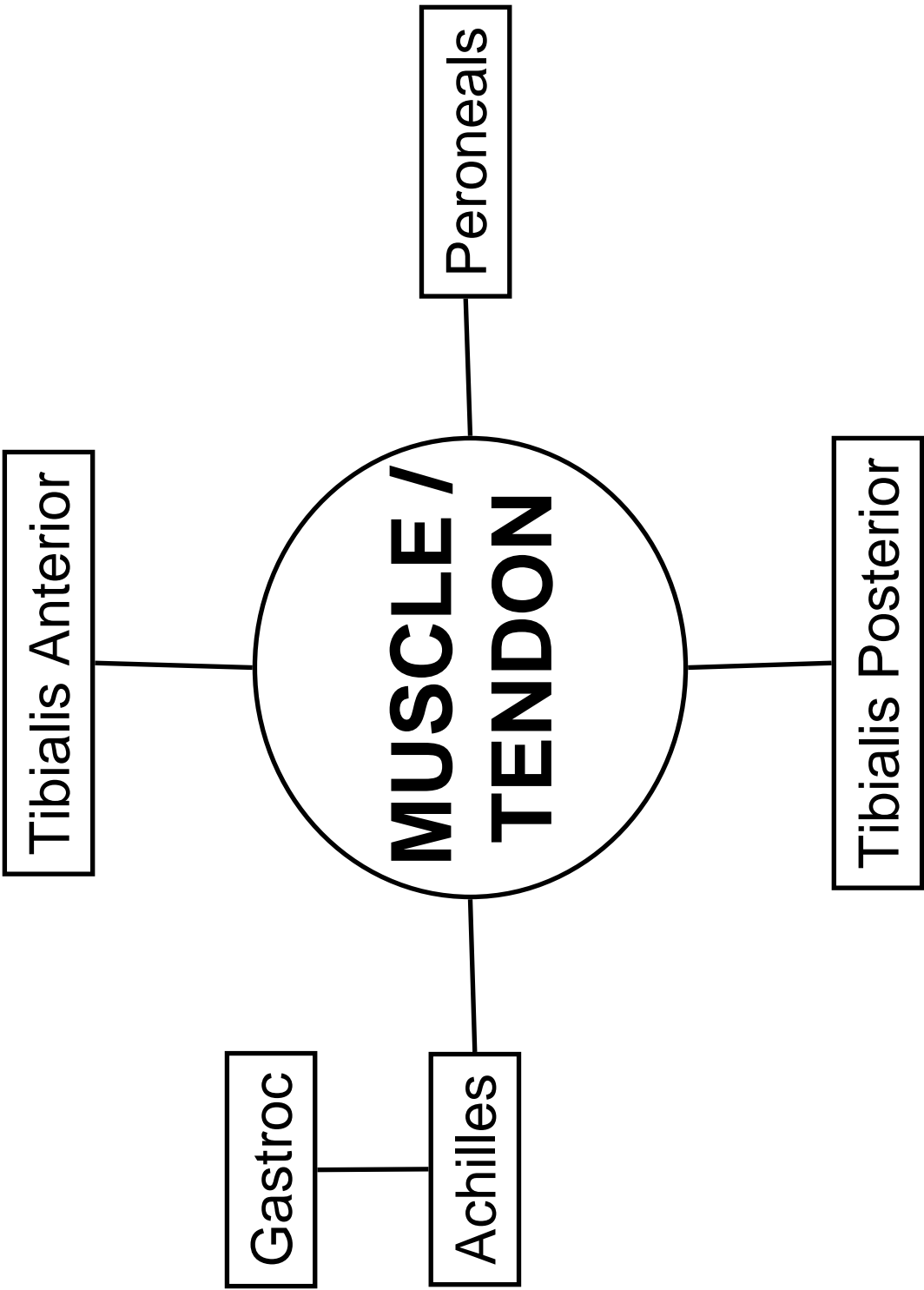
VAN

Halen





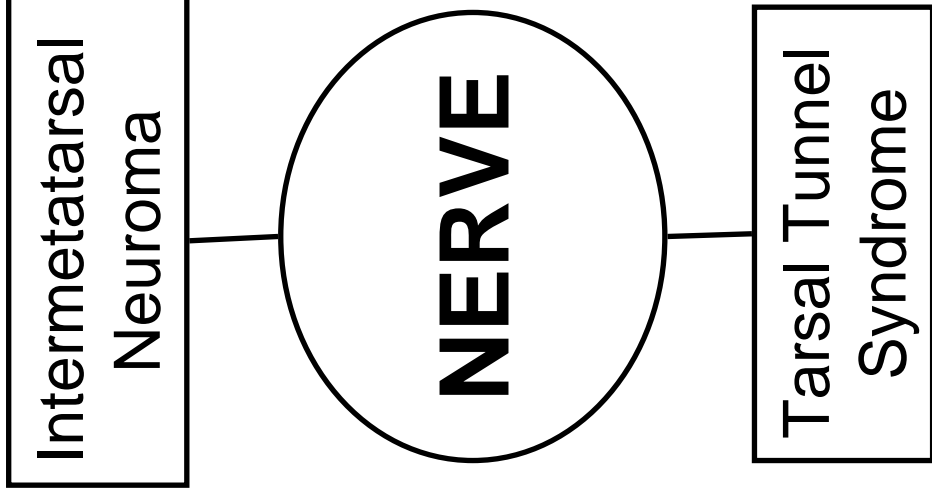




**BURSA**

**Retrocalcaneal  
Bursitis**





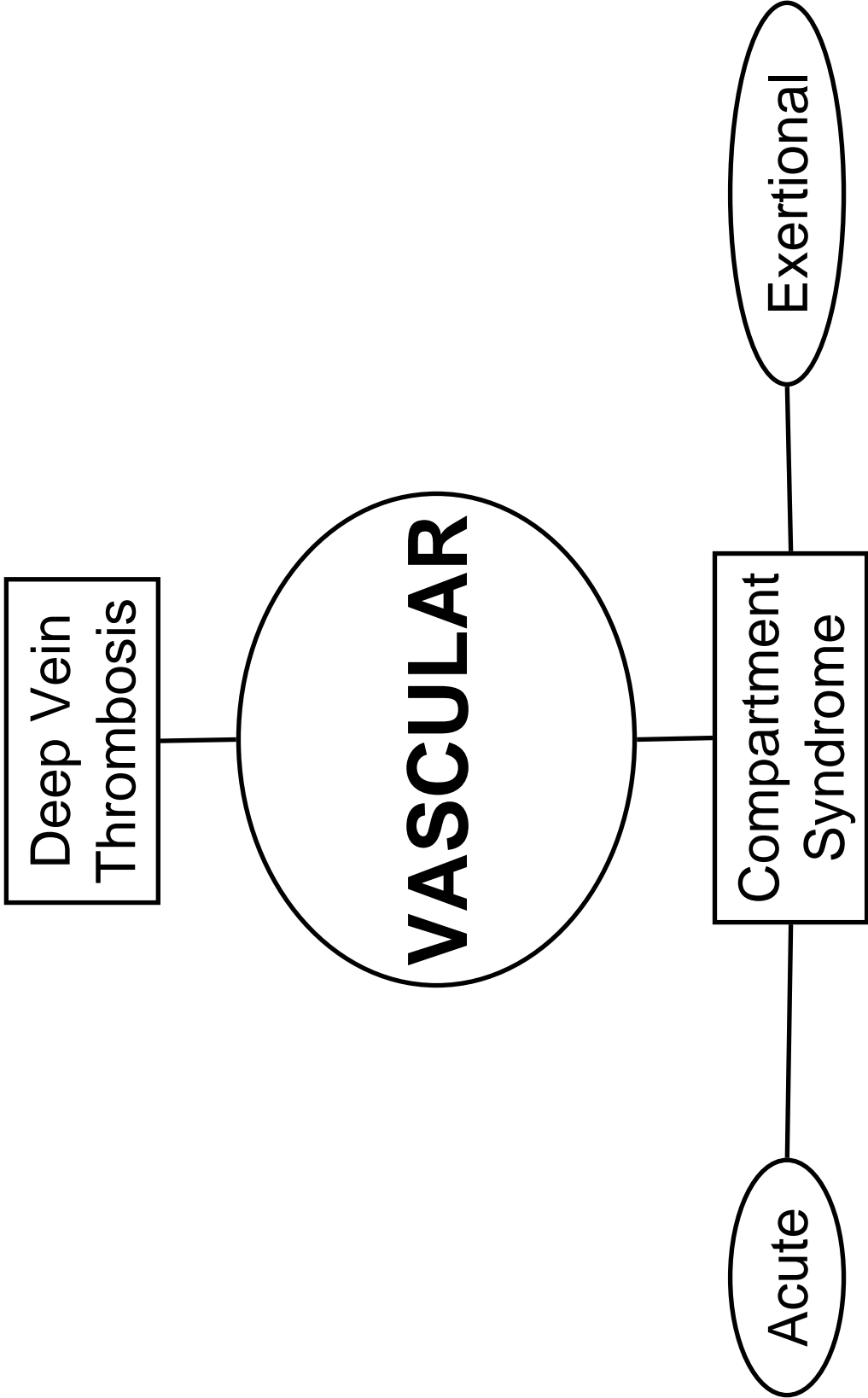
Deep Vein  
Thrombosis

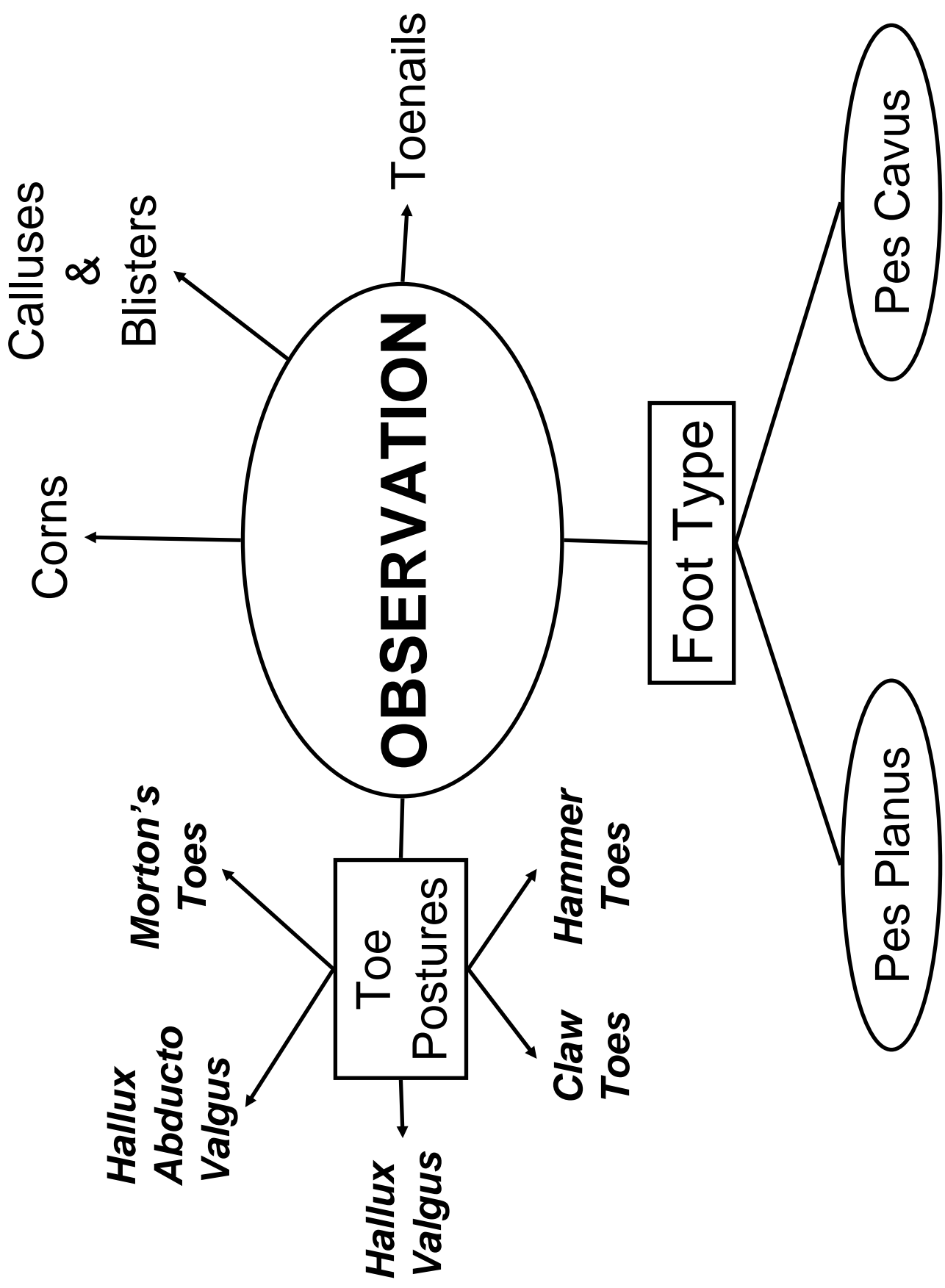
**VASCULAR**

Compartment  
Syndrome

Acute

Exertional





## FOOT AND TOES PALPATION GUIDE

### Medial Structures

First Metatarsal

First MTP Joint

First Cuneiform

Navicular

Talar Head

Sustentaculum Tali

Spring Ligament

Calcaneous

Flexor Hallicus Longus

Flexor Digitorum Longus

Tibialis Posterior

Posterior Tibial Artery

### Lateral Structures

Fifth Metatarsal

Fifth MTP Joint

Styloid Process

Cuboid

Lateral Border -

Calcaneous

Peroneal Tendons

### Dorsal Structures

Metatarsal Heads

Extensor Hallicus Longus

Extensor Digitorum Longus

Rays

Cuneiforms

Tibialis Anterior

Navicular

Dome of Talus

Inferior Extensor Retinaculum

Dorsalis Pedis Artery

Sinus Tarsi

Extensor Digitorum Brevis

### Plantar Structures

Metatarsal Heads

Sesmoid Bones

Plantar Fascia

Medial Calcaneal Tubercle

## ANKLE AND LOWER LEG PALPATION GUIDE

### Lateral Structures

Head of the Fibula

Peroneus Longus  
Peroneus Brevis

Shaft of the Fibula

Anterior Tibiofibular Ligament  
Interosseous Membrane  
Superior Peroneal  
Retinaculum

Lateral Malleolus

Calcaneofibular Ligament  
Anterior Talofibular Ligament  
Posterior Talofibular Ligament  
Peroneal Retinaculum

Peroneal Tubercle

Cuboid

Base of the 5th Metatarsal

Peroneus Tertius

### Anterior Structures

Anterior Tibial Shaft

Tibialis Anterior  
Extensor Hallicus Longus  
Extensor Digitorum Longus

Dome of Talus

Extensor Retinacula  
Dorsalis Pedis Artery

### Medial Structures

Medial Malleolus

Deltoid Ligament  
Flexor Hallicus Longus  
Flexor Digitorum Longus  
Tibialis Posterior  
Posterior Tibial Artery

Sustenaculum Tali

Spring Ligament

Navicular Tuberosity

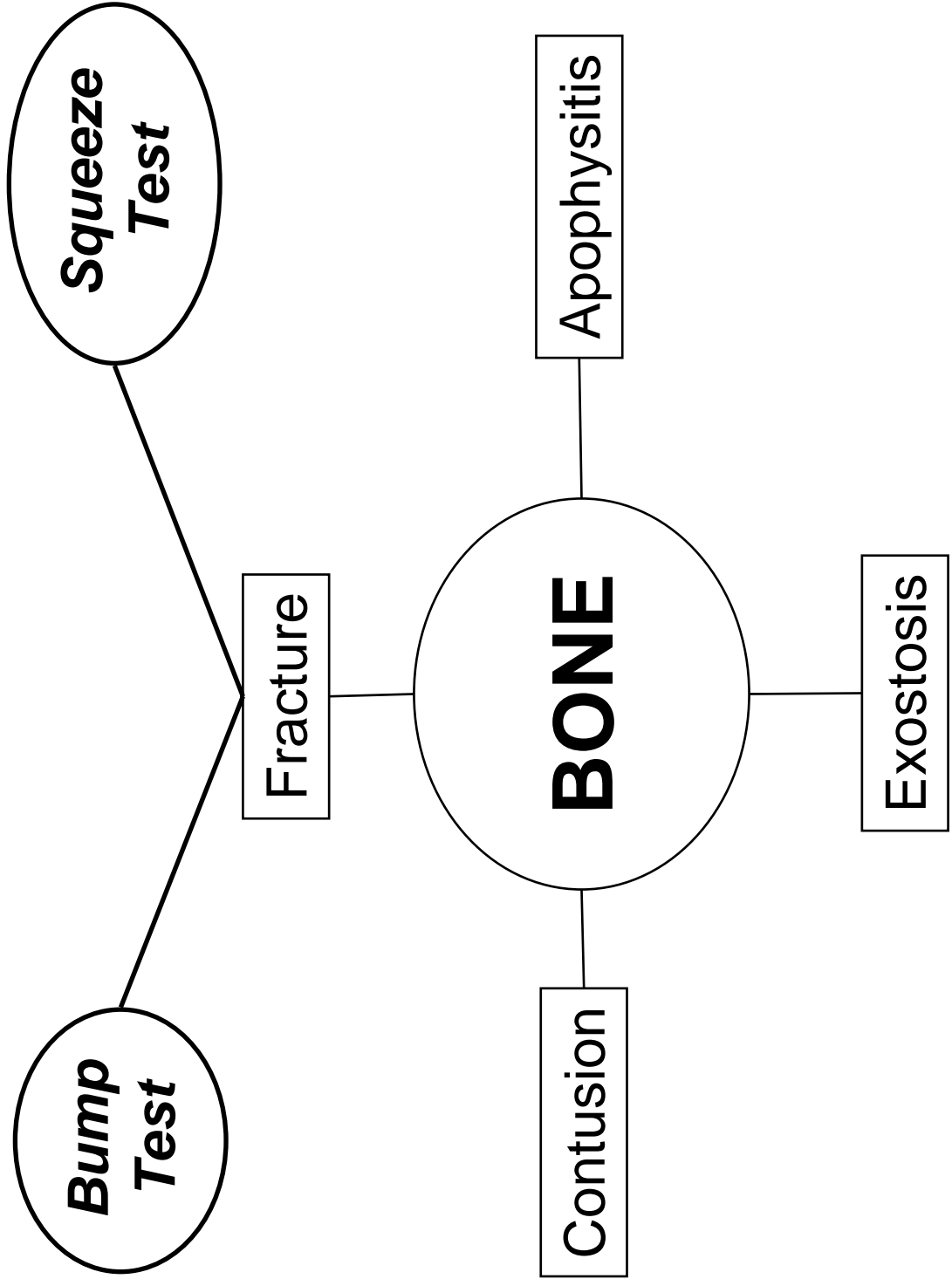
Tibialis Posterior

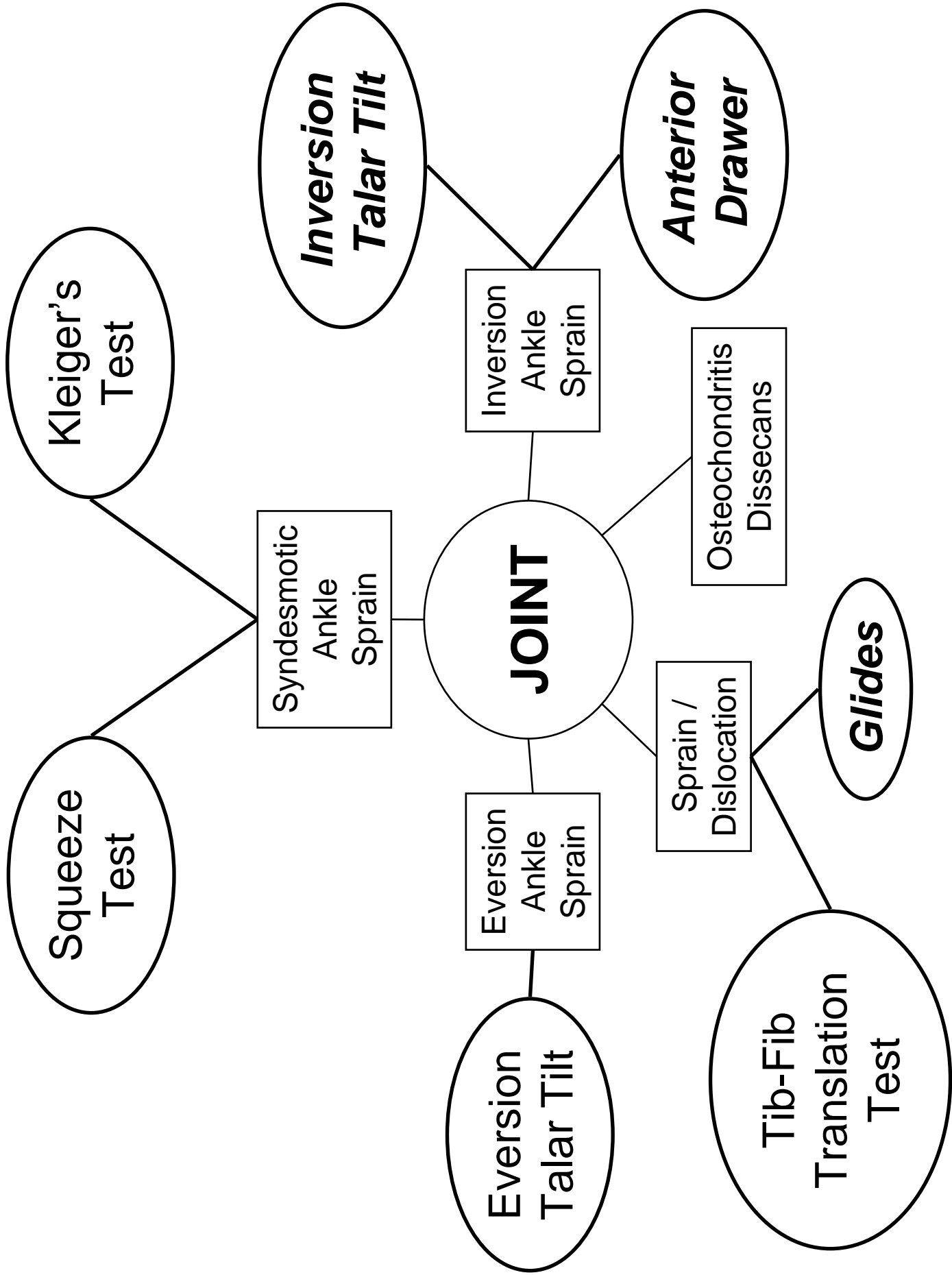
Posterior Structures

Calcaneous

Gastroc-Soleus Complex  
Achilles Tendon  
Subcutaneous Calcaneal  
Bursa

Subtendinous Calcaneal  
Bursa







# Goniometry

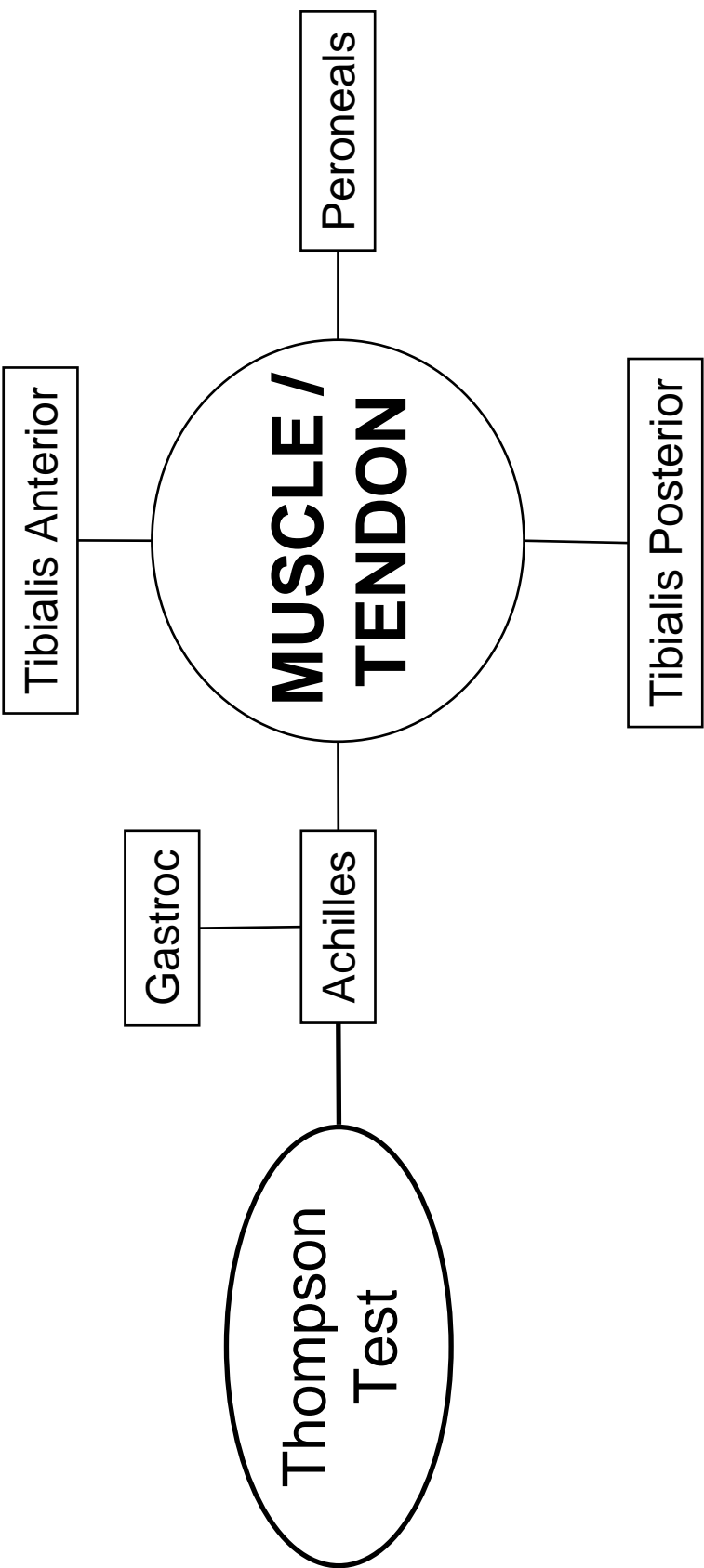
Motion	Normal ROM	Stationary Arm	Axis of Rotation	Moving Arm
IP Flexion				
IP Extension				
MTP Flexion				
MTP Extension				
MTP Abduction				
MTP Adduction				

# Goniometry

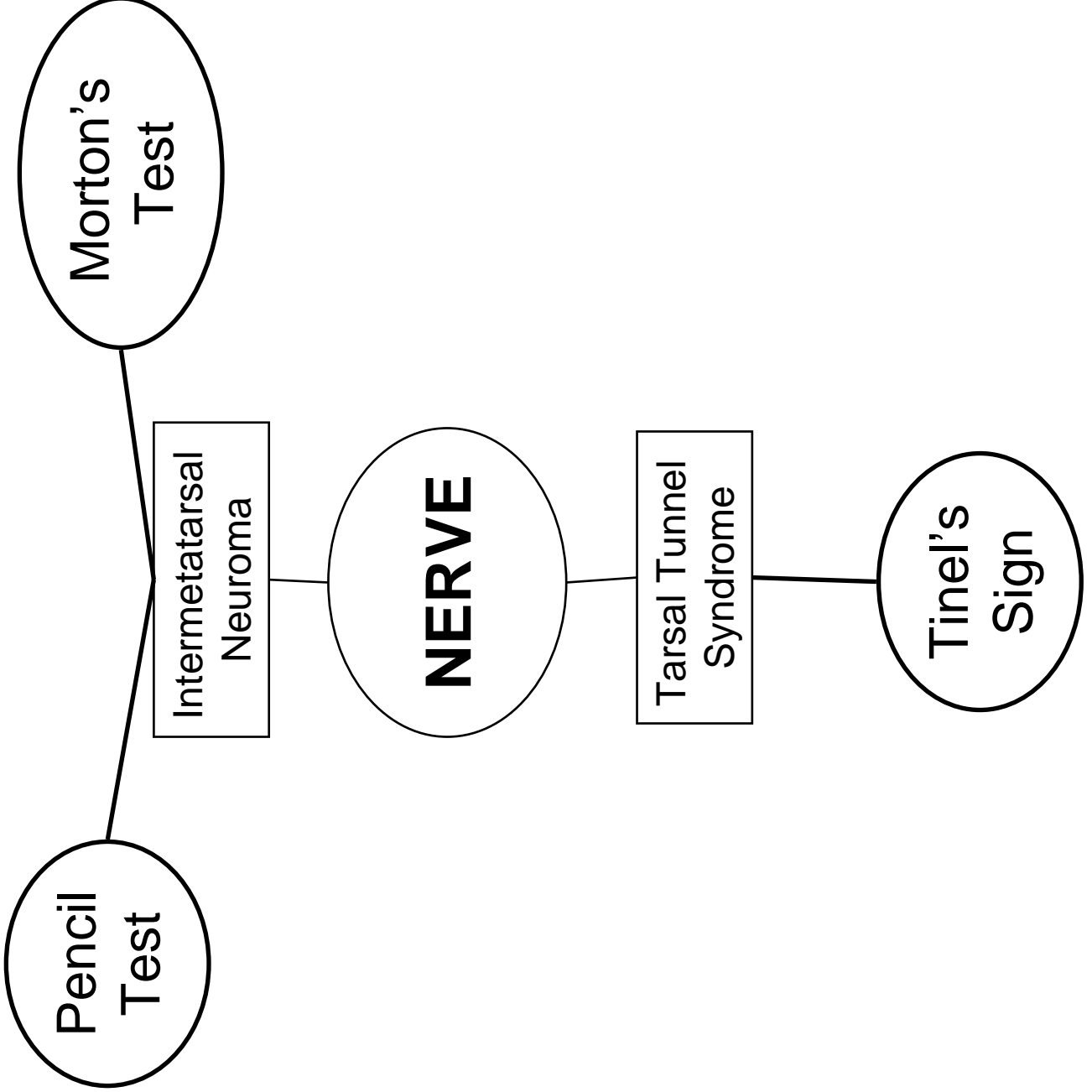
Motion	Normal ROM	Stationary Arm	Axis of Rotation	Moving Arm
Rearfoot Inversion				
Rearfoot Eversion				
Plantar Flexion				
Dorsi Flexion				

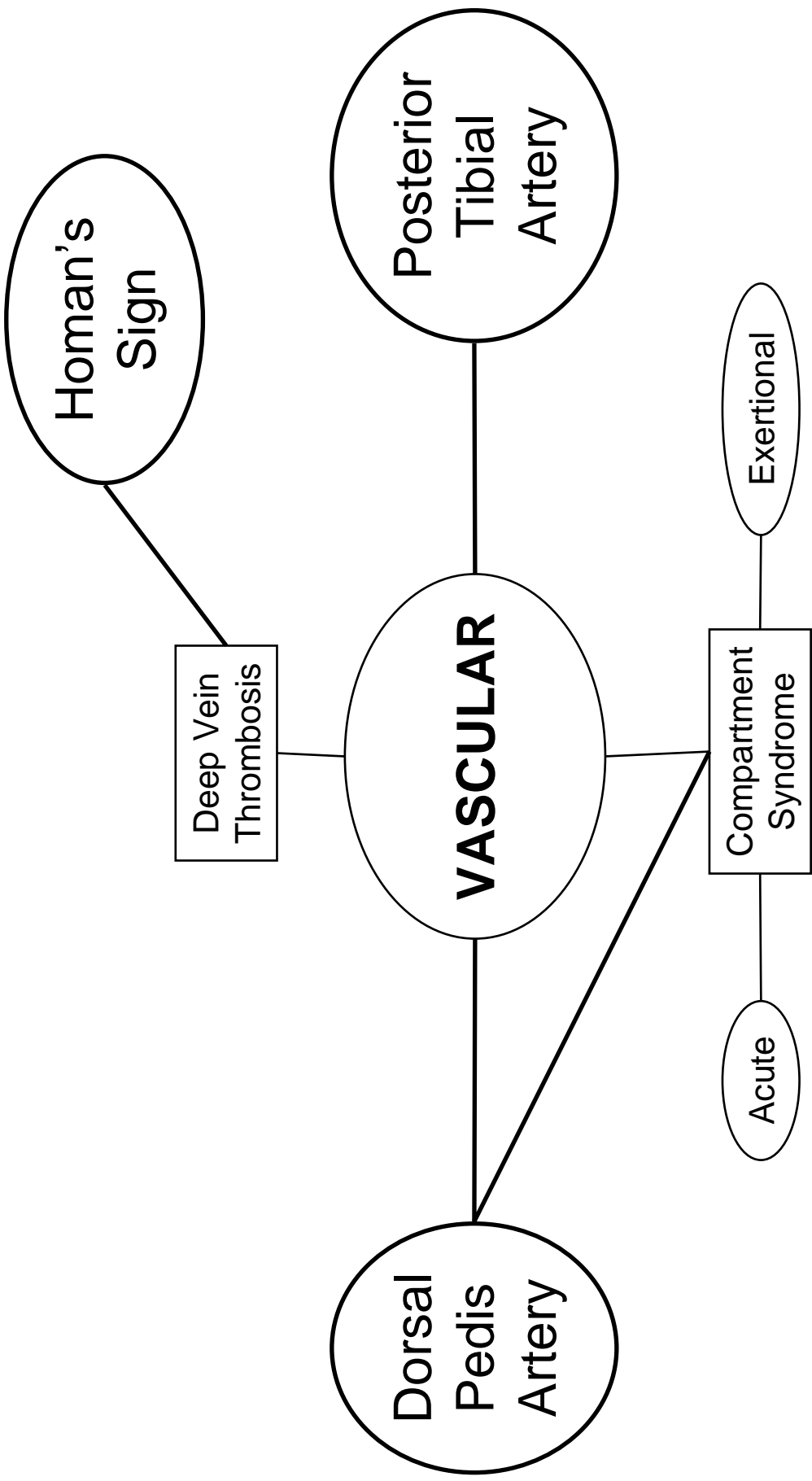
# Goniometry Worksheet

	Subject 1 _____		Subject 2 _____	
	Evaluator A _____	Evaluator B _____	Evaluator A _____	Evaluator B _____
<b>MTP</b>				
Extension				
Flexion				
Adduction				
Abduction				
<b>Subtalar</b>				
Eversion				
Inversion				
<b>Talocrural</b>				
PF				
DF				



	PROM	AROM
	KNEE	KNEE
	ANKLE	ANKLE
Gastroc		
Soleus		





## Bone

Injury	Mechanisms	Special Tests
Jones Fracture		
Tibial Stress Fracture		Squeeze Test Bump Test

## Joint

Injury	Mechanisms	Special Tests
Turf Toe		
Everson Ankle Sprain		Anterior Drawer Inversion Talar Tilt
	Dorsiflexion with external rotation of the foot	
		Cuboid glide – plantar to dorsal



## Muscle / Tendon

Injury	Mechanisms	Special Tests
Plantar Fasciitis		
		Thompson Test
Peroneal Tendon Subluxation		
Tibialis Anterior Strain		
Tibialis Posterior Strain		

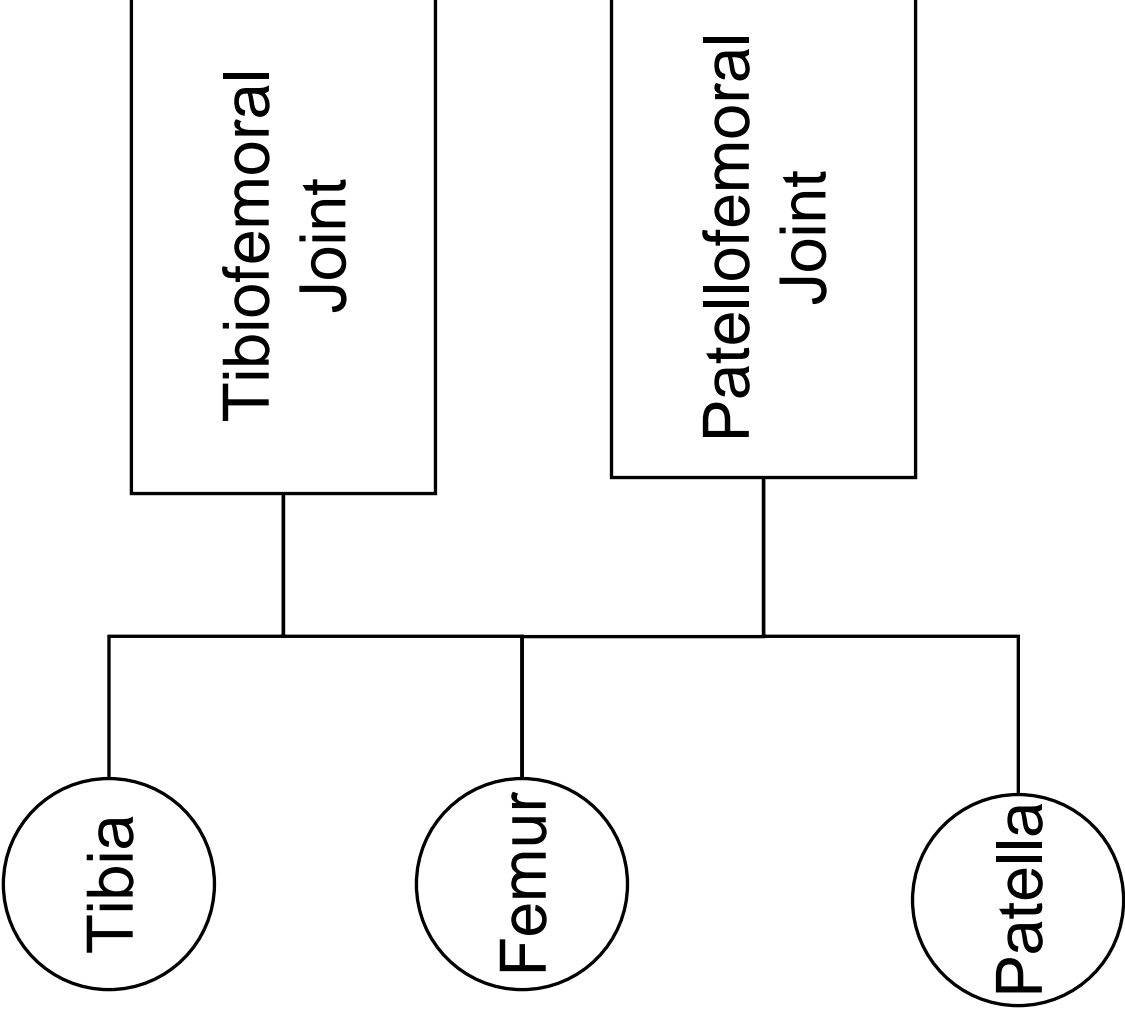
## **Nerve**

<b>Injury</b>	<b>Mechanisms</b>	<b>Special Tests</b>
Intermetatarsal Neuroma		
		Tinel's Sign

## **Vascular**

<b>Injury</b>	<b>Mechanisms</b>	<b>Special Tests</b>
Anterior Compartment Syndrome		
		Deep Vein Thrombophlebitis



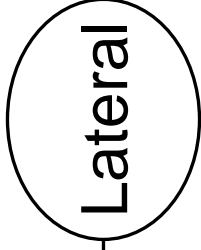
Knee



What are the consequences?

Structure	Function
Femur	
Medial condyle extends further distally	
Medial condyle is larger	
Lateral border of the trochlear groove is larger	
Trochlear groove is deeper inferiorly	
Tibia	
Condyles are smaller than femoral condyles	

*Lateral*



*Medial*

*Anterior*

*Posterior*

# Purpose of the Menisci

1)

2)

3)

4)

5)

6)

7)

*Lateral*

IT Band

LCL

ACL

**Ligaments**

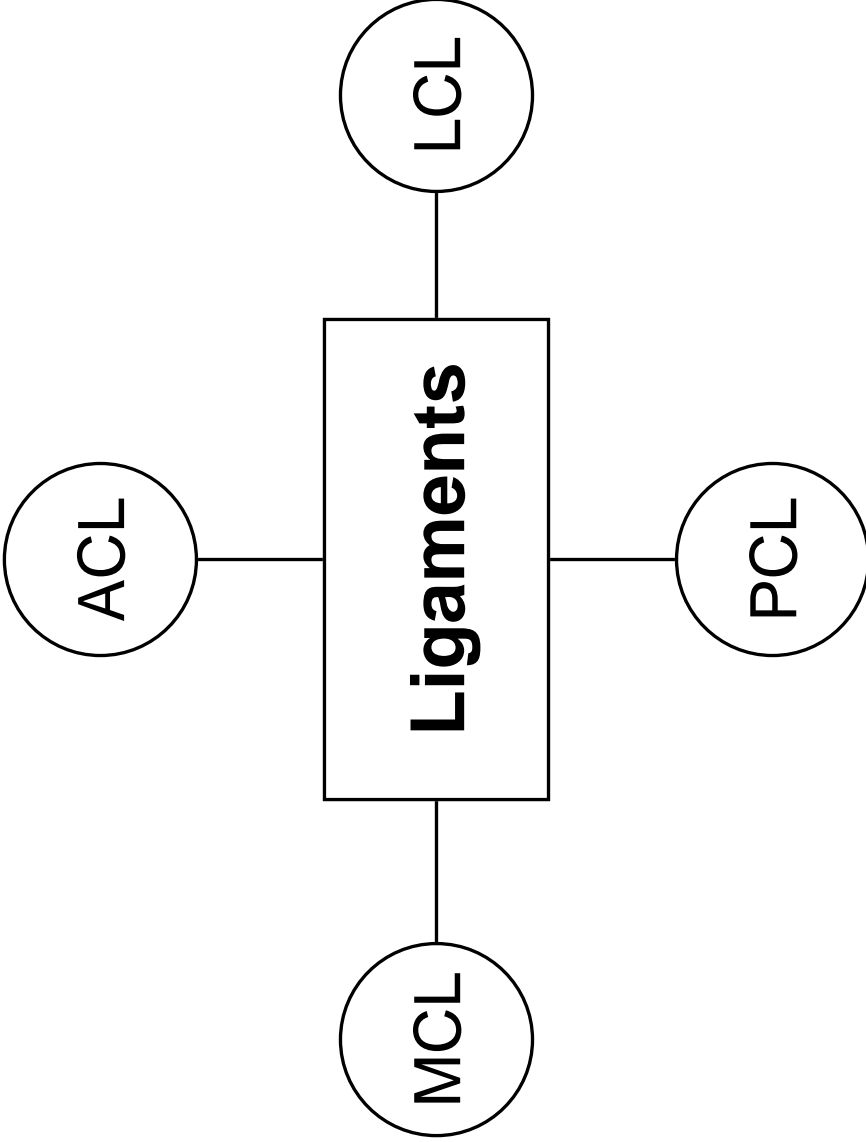
PCL

MCL

*Anterior*

*Posterior*

*Medial*





# Ligaments

Ligament	Connects	Restrains
ACL		
PCL		
MCL		
LCL		

Extensors

*Rectus Femoris*

*TFL*  
(0-30°)

*Vastus Lateralis*

*Vastus Medialis*

*Vastus Intermedius*

*Sartorius\**

*Gracilis\**

*Popliteus*

*Semimembranosus*

*Semitendinosus\**

*Plantaris*

*Gastrocnemius*

IR

ER

*Biceps Femoris*

*TFL*  
(45-145°)

Flexors

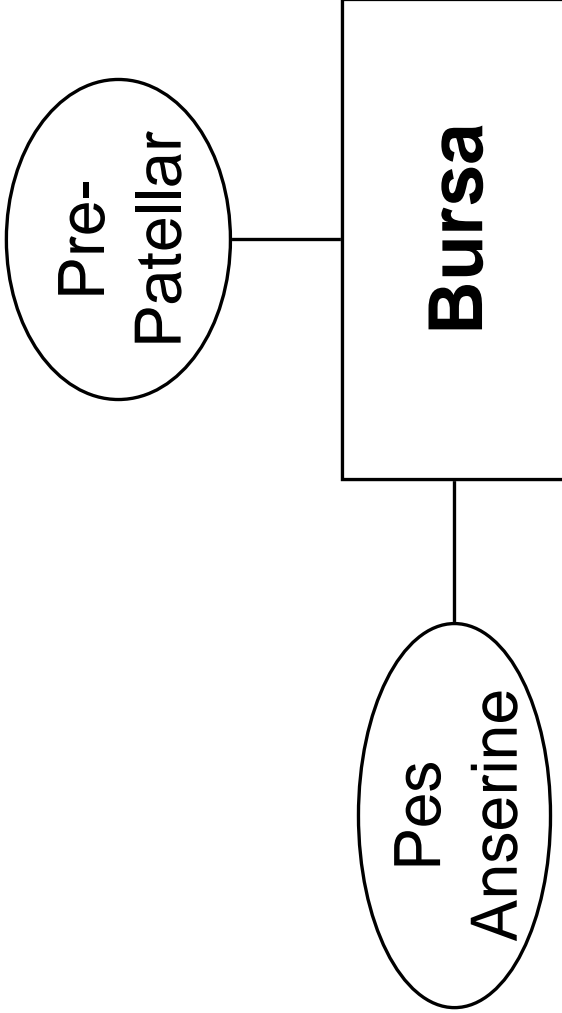
\* *Pes Anserine*

# Muscle – Joint Interaction

Motion	Prime Mover(s)
Flexion	
Extension	
IR	
ER	

*Lateral*

*Anterior*

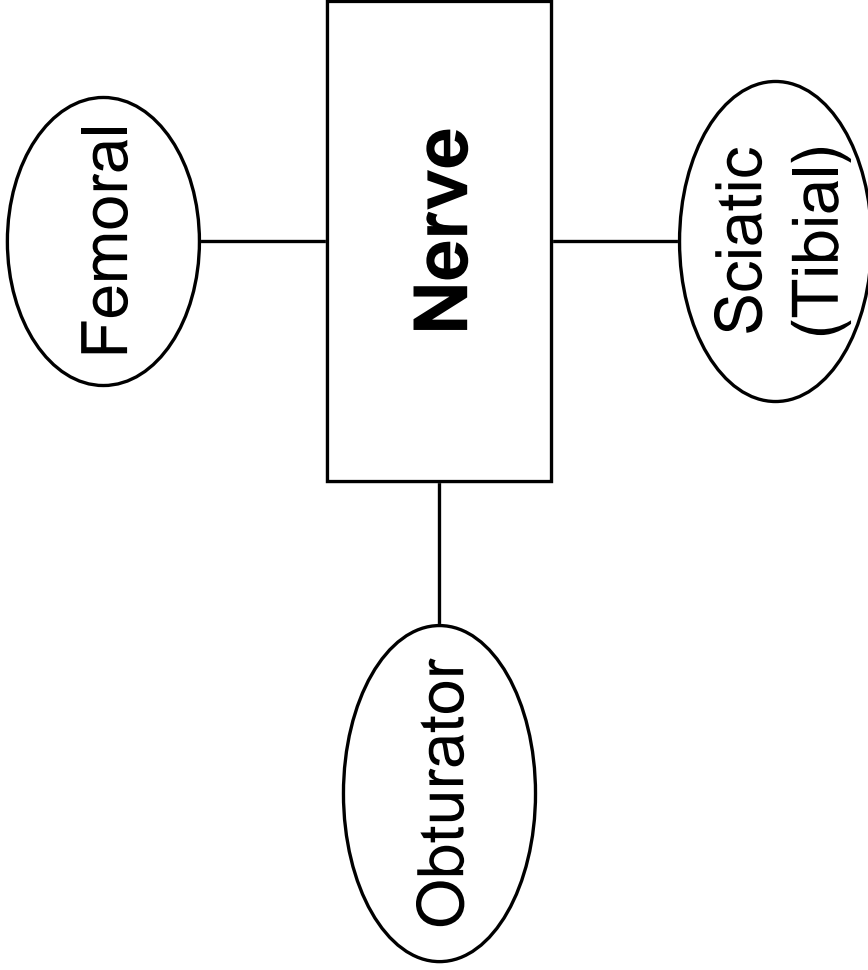


*Posterior*

*Medial*

*Lateral*


*Anterior*




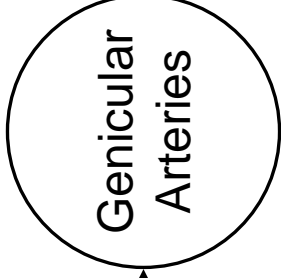
*Posterior*

*Medial*

*Anterior*

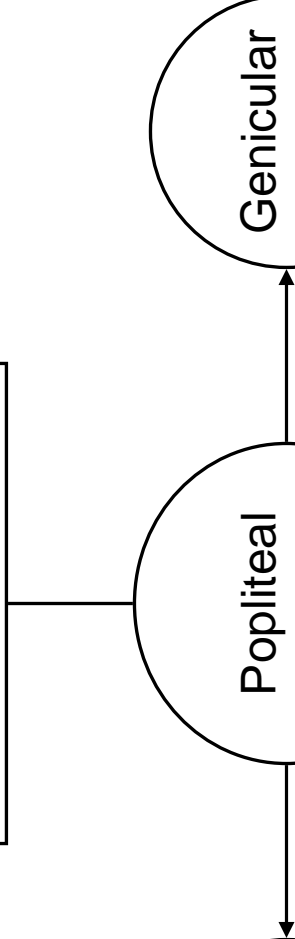


*Lateral*



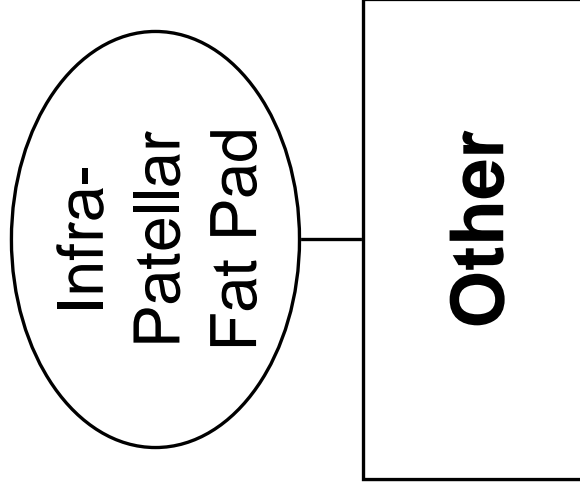
*Medial*

*Posterior*



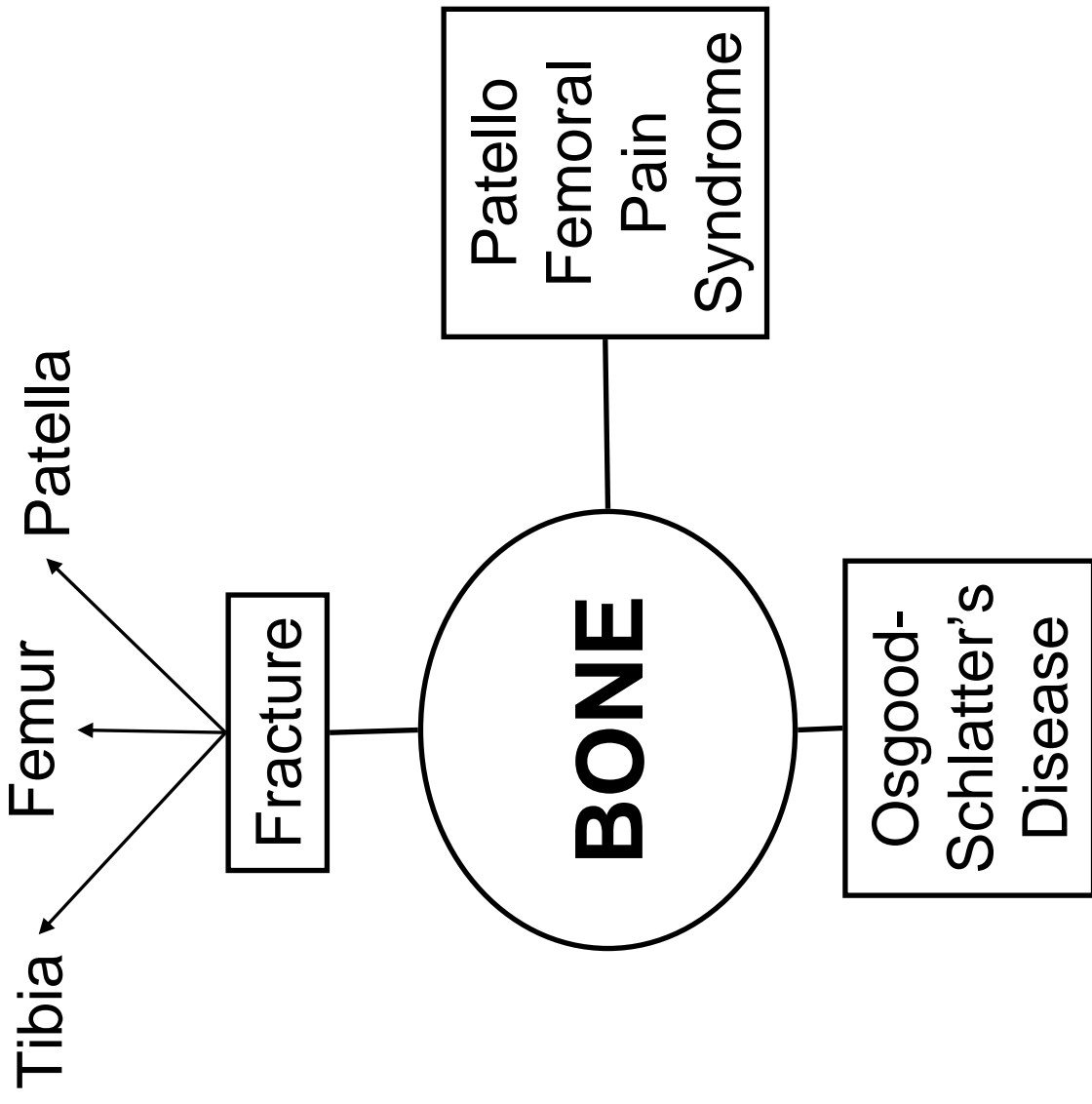
*Lateral*

*Anterior*



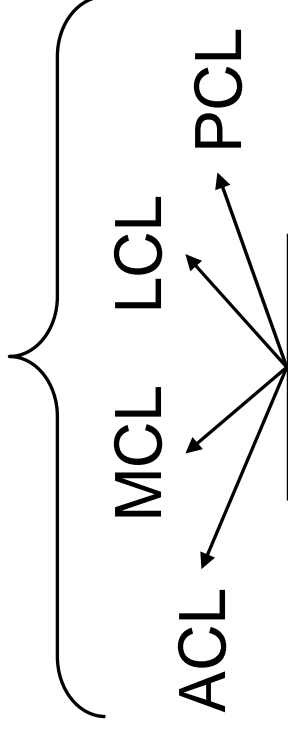
*Posterior*

*Medial*





*Rotational Instabilities*



Sprains

**JOINT**

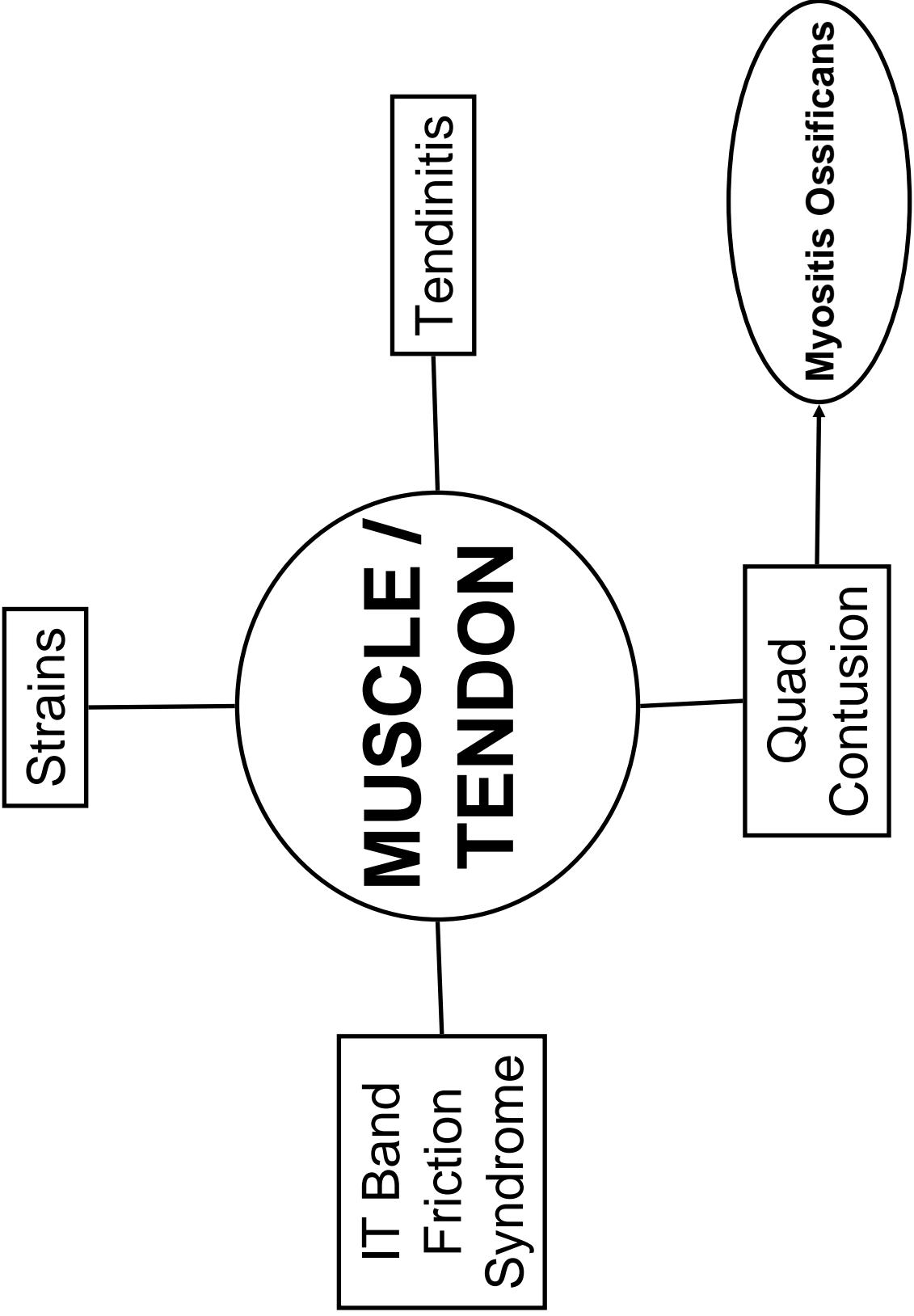
Osteochondral Defects

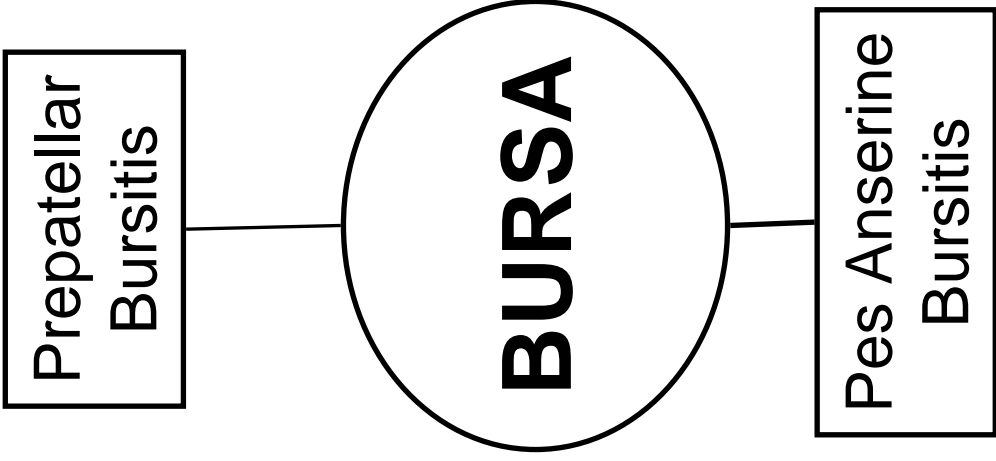
Meniscal Tears

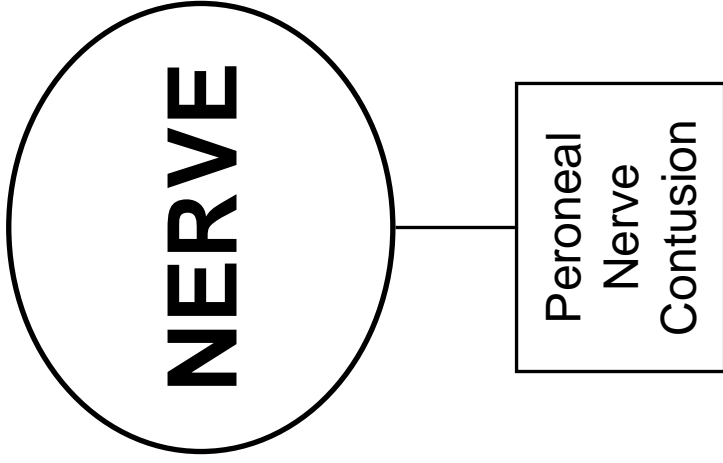
Plica

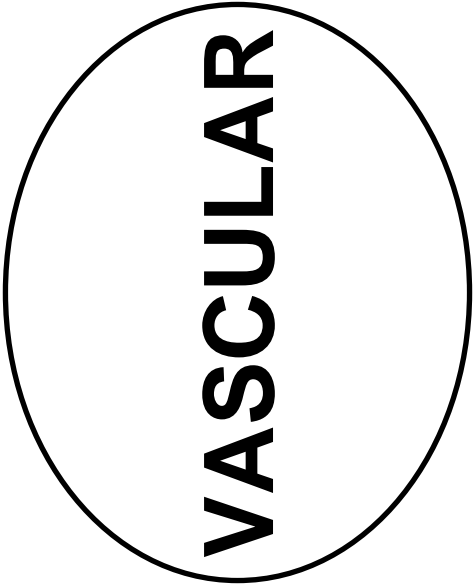
Popliteal Cyst

Osteochondritis Dissecans

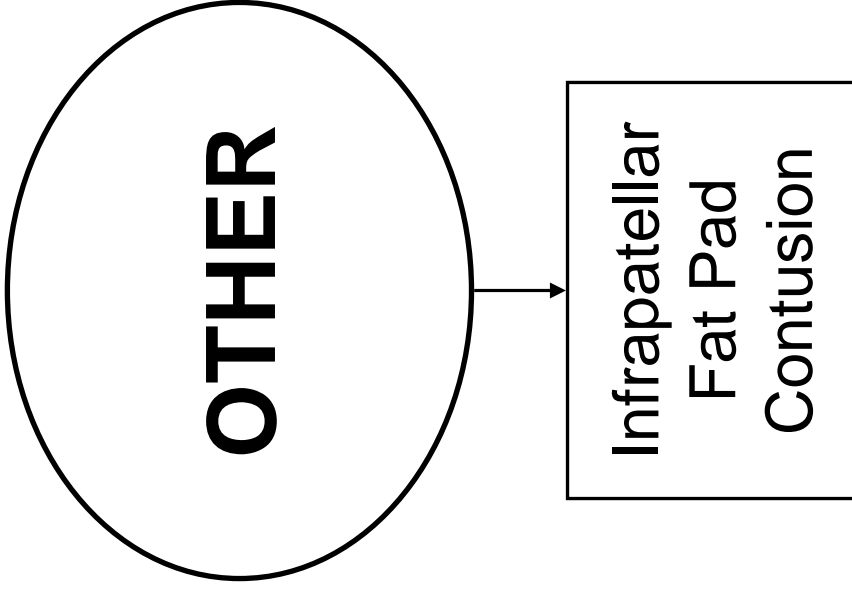


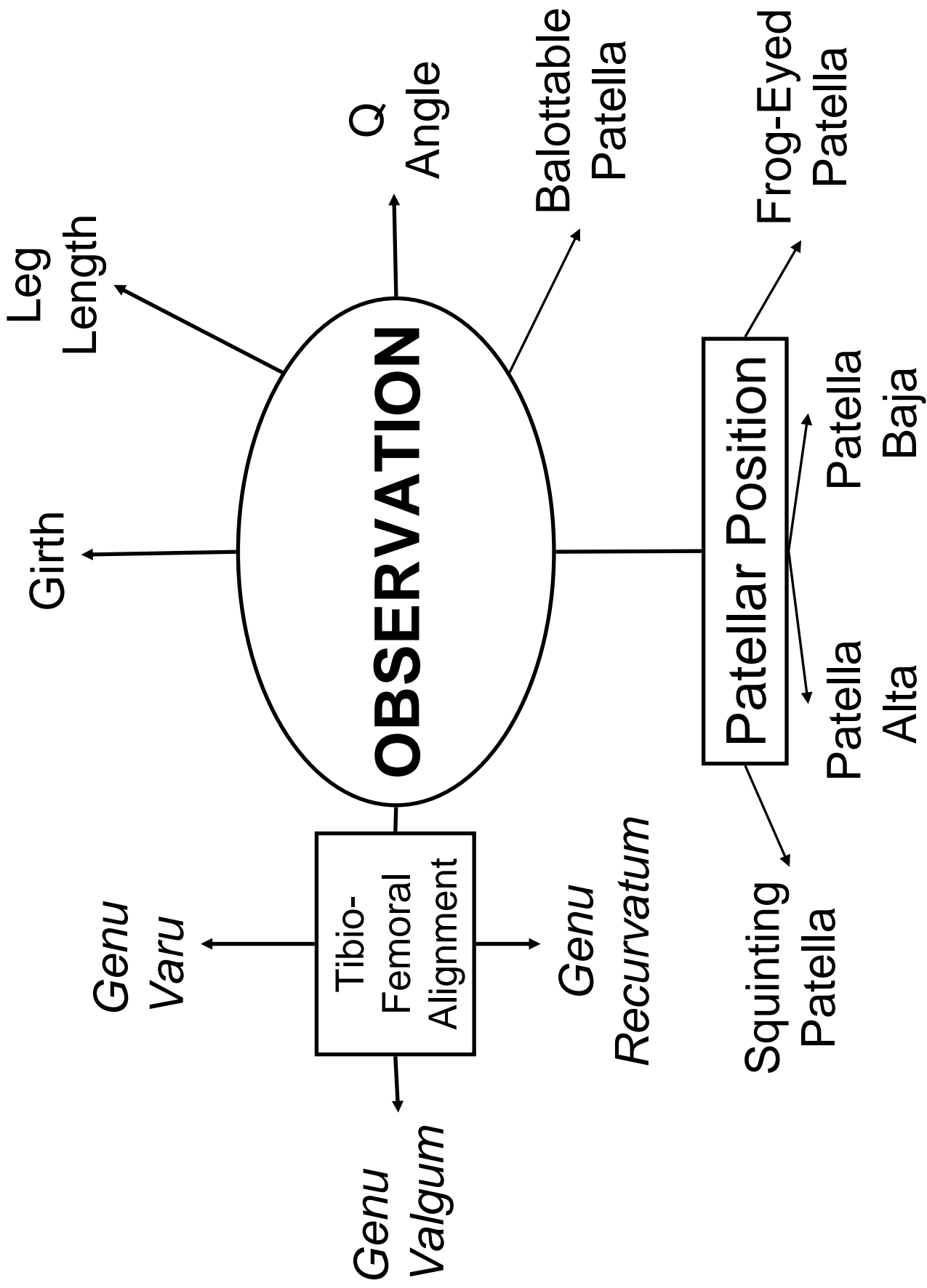


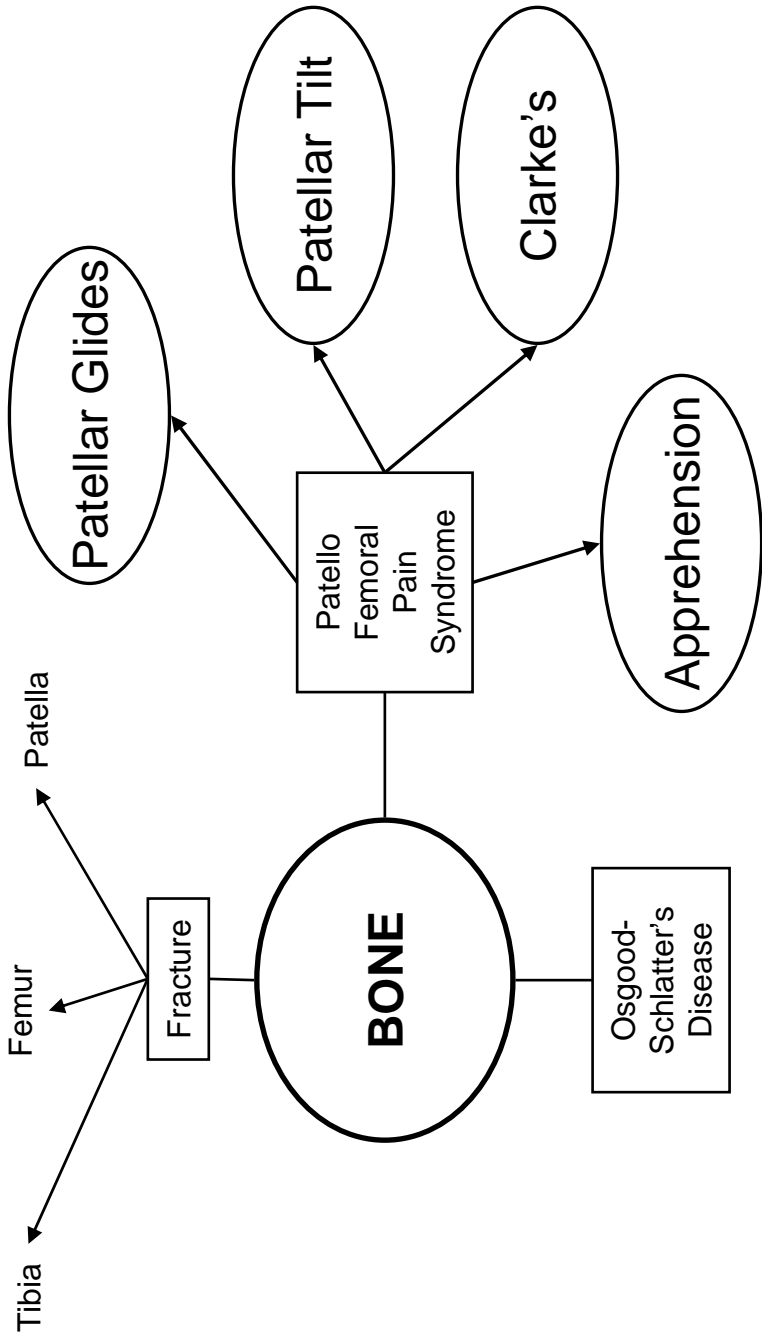




**VASCULAR**









## KNEE PALPATION GUIDE

### Anterior Structures

Tibial Tuberosity

Patellar Tendon

Patella

Quadriceps Tendon  
Quadriceps Muscle Group  
Sartorius

### Medial Structures

Medial Tibial Plateau

Medial Meniscus  
Medial Collateral Ligament  
Pes Anserine Tendon  
Semimembranosus  
Gracilis

Medial Femoral Condyle  
Medial Femoral Epicondyle

Medial Collateral Ligament

### Lateral Structures

Lateral Tibial Plateau

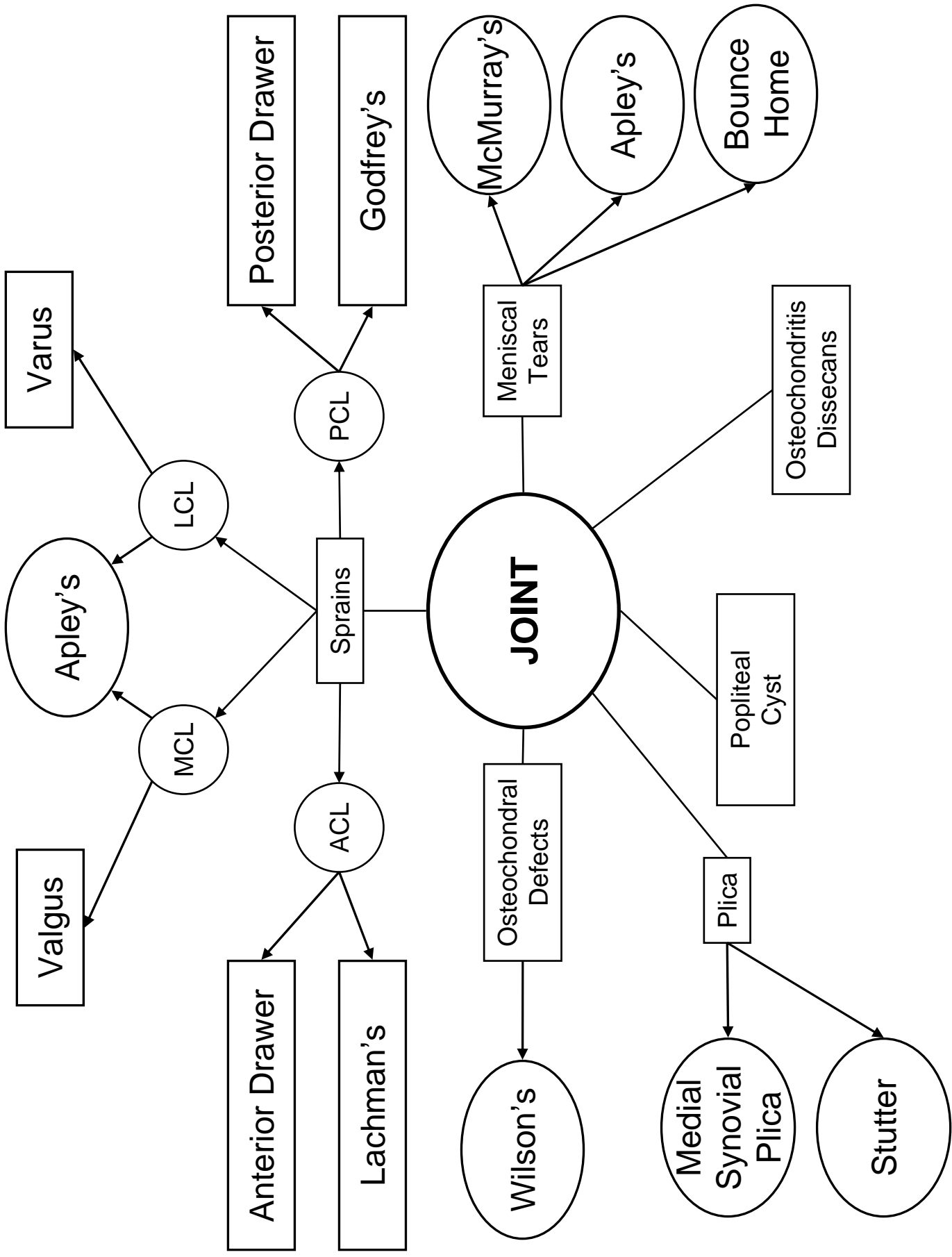
Lateral Collateral Ligament  
Iliotibial Band

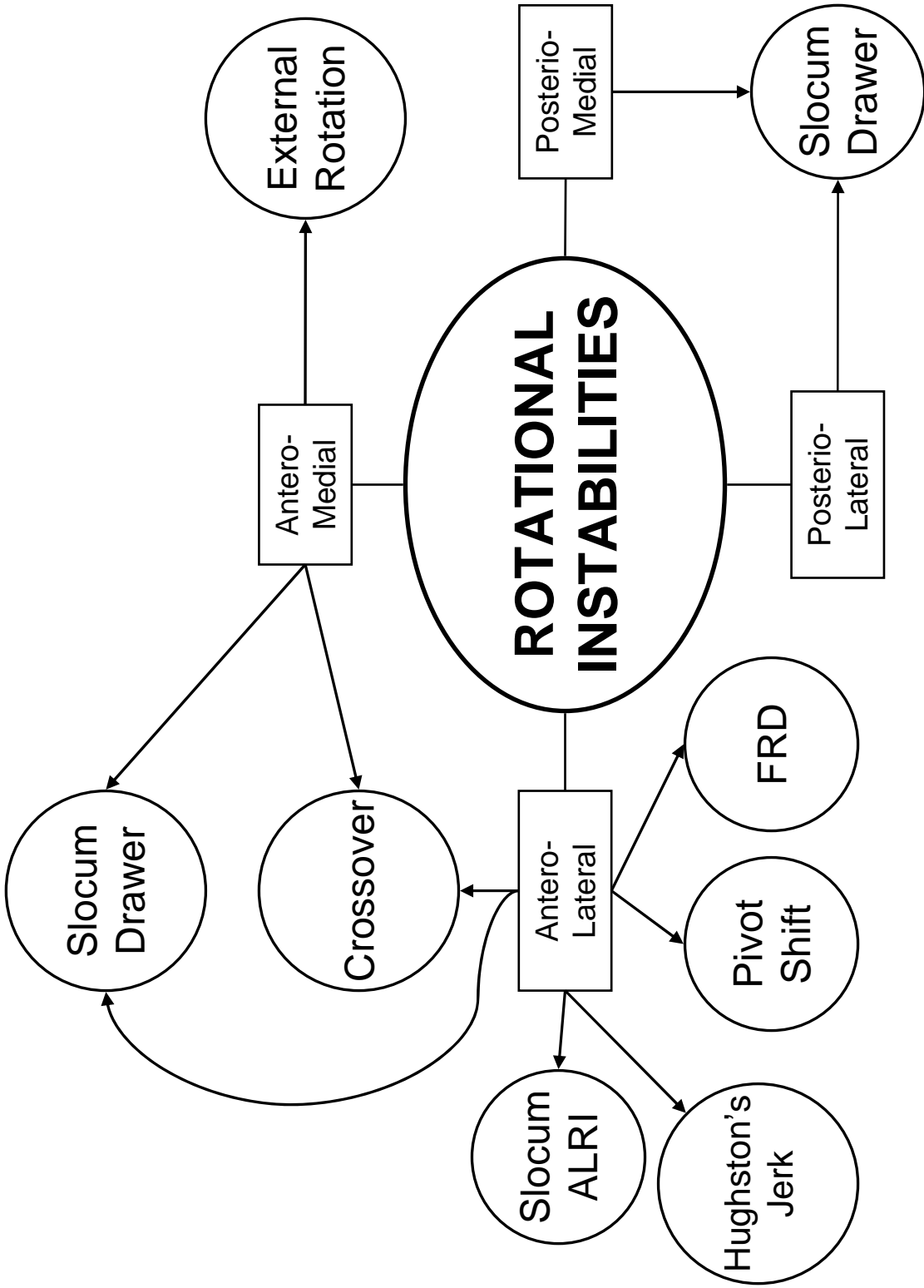
Fibular Head

Lateral Collateral Ligament  
Popliteus  
Biceps Femoris

### Posterior Structures

Popliteal Fossa  
Hamstring Muscle Group  
Heads of Gastrocnemius



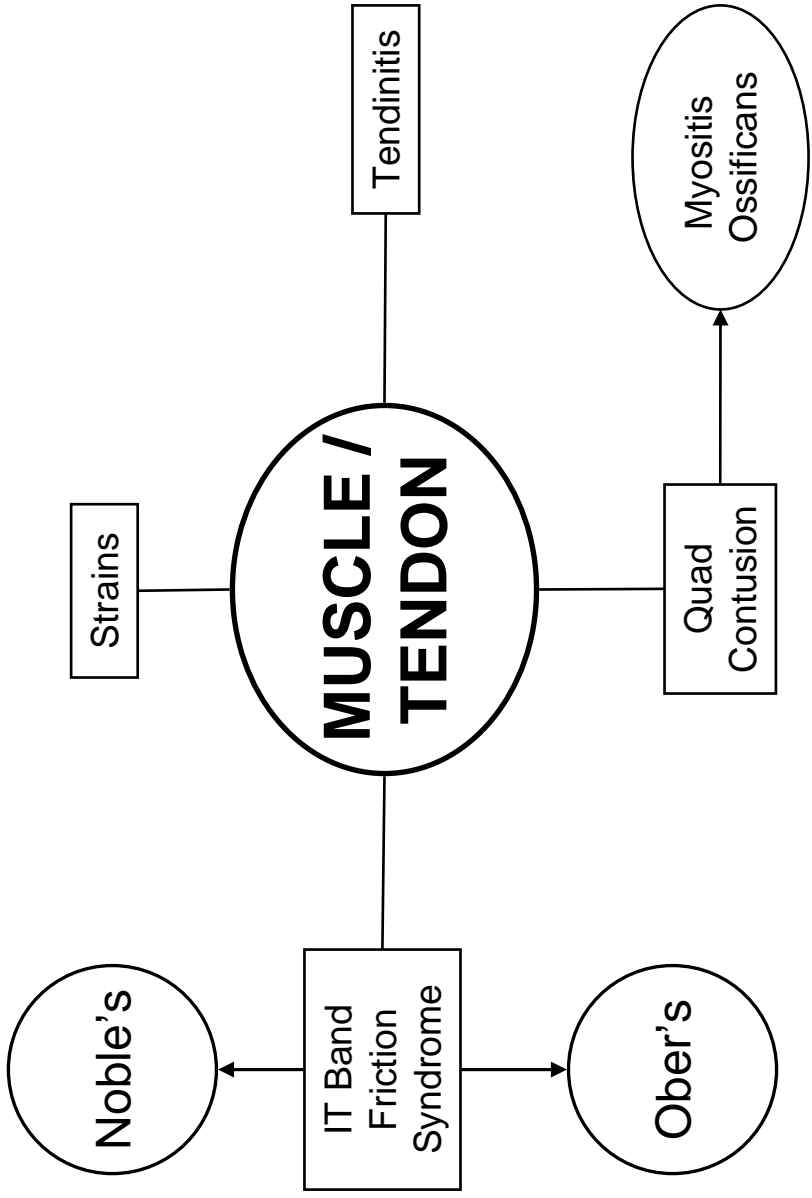


# Goniometry

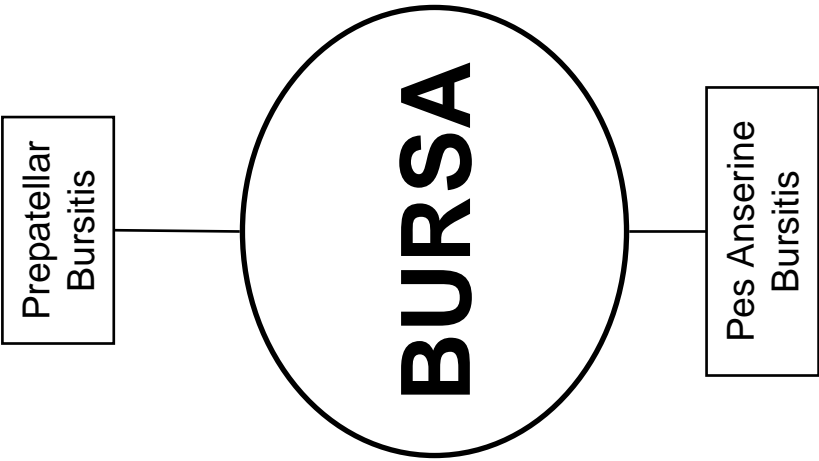
Motion	Normal ROM	Stationary Arm	Axis of Rotation	Moving Arm
Flexion				
Extension				
Internal Rotation				
External Rotation				

# Goniometry Worksheet

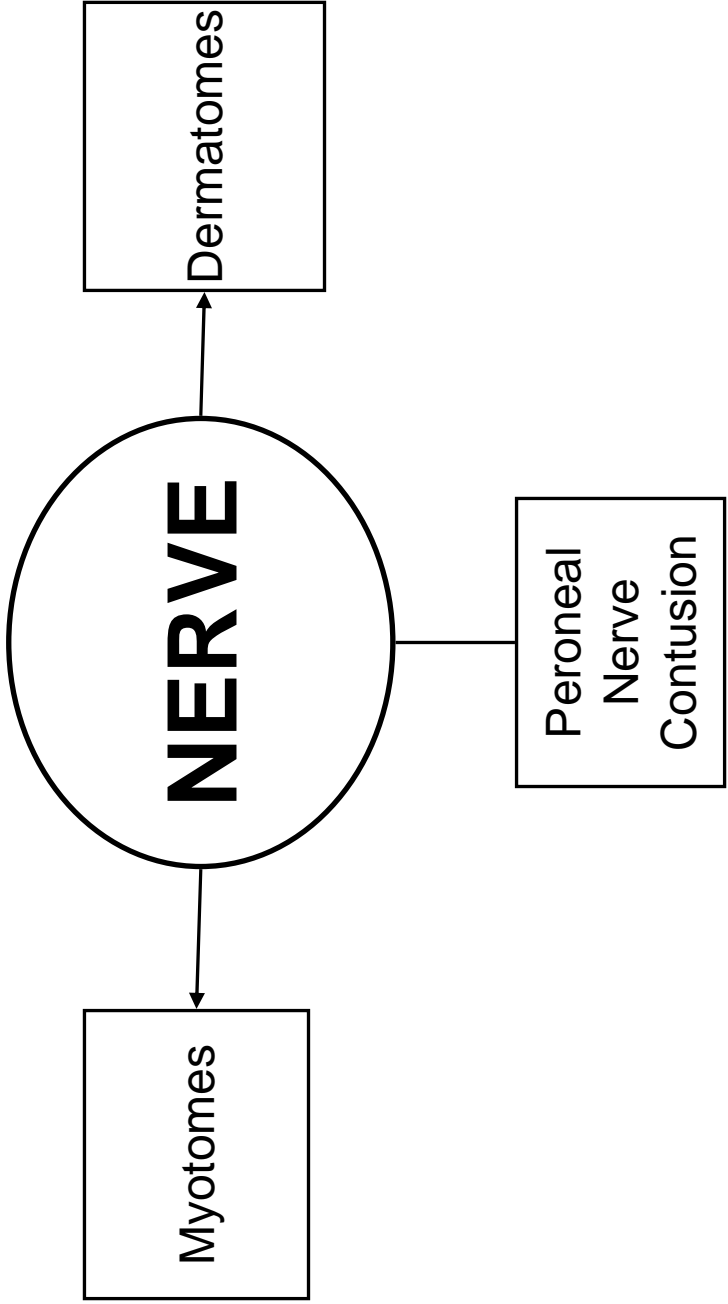
	Subject 1 _____		Subject 2 _____	
	Evaluator A _____	Evaluator B _____	Evaluator A _____	Evaluator B _____
<b>Knee</b>				
Extension				
Flexion				
IR				
ER				

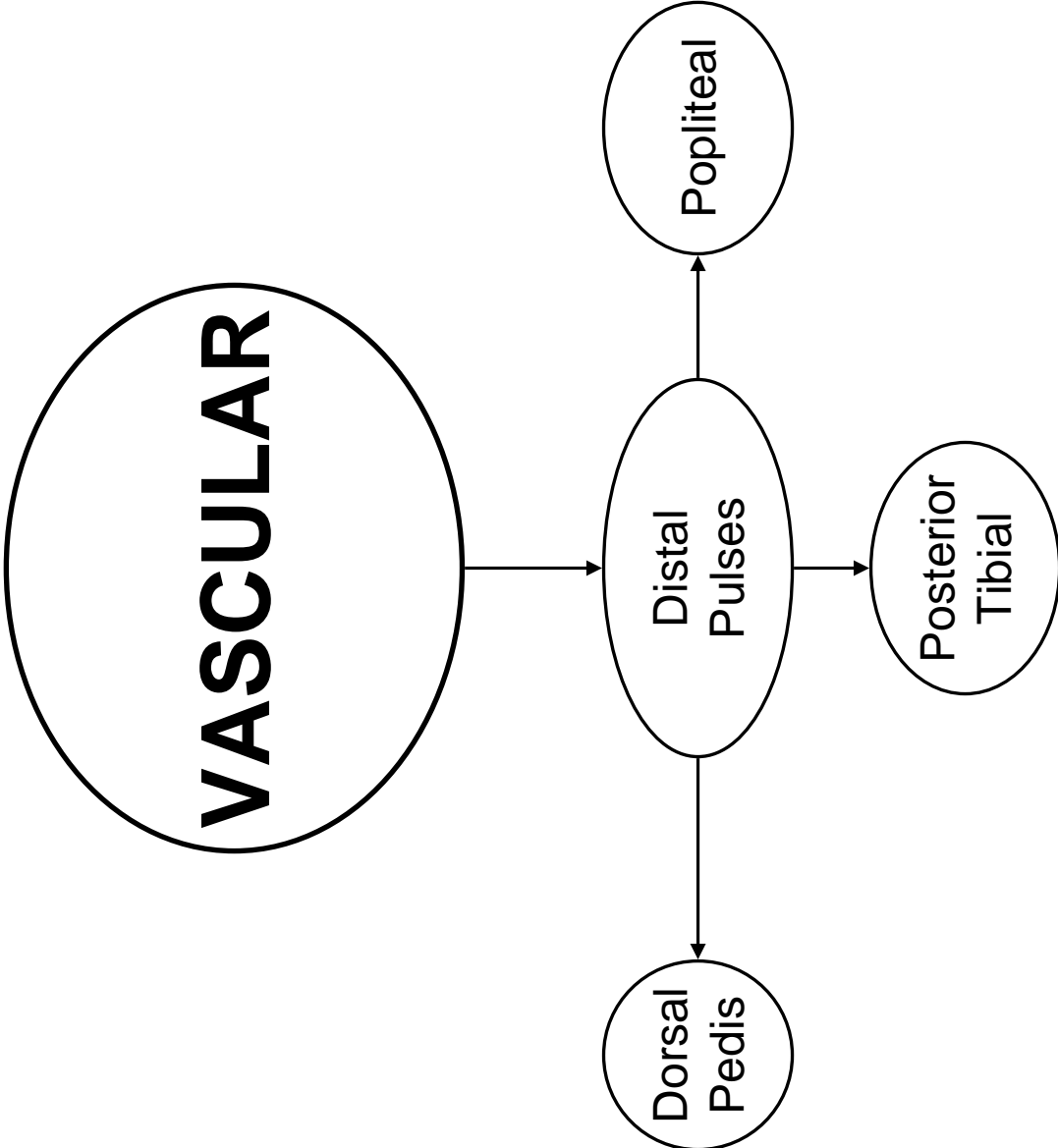


	PROM	AROM
Rectus Femoris	KNEE	KNEE
	HIP	HIP
Hamstrings		









**Kinesiology 338L**  
**Knee**  
**Checklist**

History \_\_\_\_\_

General History

Specific to this Region

Observation \_\_\_\_\_

General Inspection

Girth Measurements

Leg Length

Patellar Position

Tibiofemoral Alignment

Q-Angle

Calluses/Corns/Blisters

Palpation

Anterior Structures \_\_\_\_\_

Tibial Tuberosity

Patellar Tendon

Patella

Quadriceps Tendon

Quadriceps Muscle Group

Sartorius

Medial Structures

---

Medial Tibial Plateau

Medial Meniscus

Medial Collateral Ligament

Pes Anserine Tendon

Semimembranosus

Medial Femoral Condyle

Medial Femoral Epicondyle

Medial Collateral Ligament

Lateral Structures

---

Lateral Tibial Plateau

Lateral Meniscus

IT Band

Fibular Head

Lateral Collateral Ligament

Popliteus

Biceps Femoris

Posterior Structures

---

Popliteal Fossa

Hamstring Muscle Group

Heads of Gastrocnemius

Stress

Bone

---

Bump Test

Squeeze Test

Joint

PROM

---

Flexion

Extension

Internal Rotation

External Rotation

Joint Glides

---

Tibiofemoral

Patellofemoral

Special Tests

---

Balottable Patella

Patellar Tilt

Clarke's

Apprehension

Anterior Drawer

Lachman's

Valgus

Varus

Godfrey's

Posterior Drawer

McMurray's

- Apley's
- Bounce Home
- Stutter
- Medial Synovial Plica
- Wilson's
- Slocum Drawer
- Crossover
- Slocum ALRI
- FRD
- Hughston's Jerk
- Pivot Shift
- External Rotation

Muscle/Tendon

A/P/RRROM

- Flexion
  - Extension
  - Internal Rotation
  - External Rotation
- 

Special Tests

- Noble's
  - Ober's
- 

Nerve

DTR

- S1/S2
  - L3/L4
  - L5/S1
-

Dermatomes

---

L1

L2

L3

L4

L5

S1

S2

Myotomes

---

L2

L3

L4

L5

S1

S2

Vascular

Distal Pulses

---

Doral Pedis A.

Post Tib A.

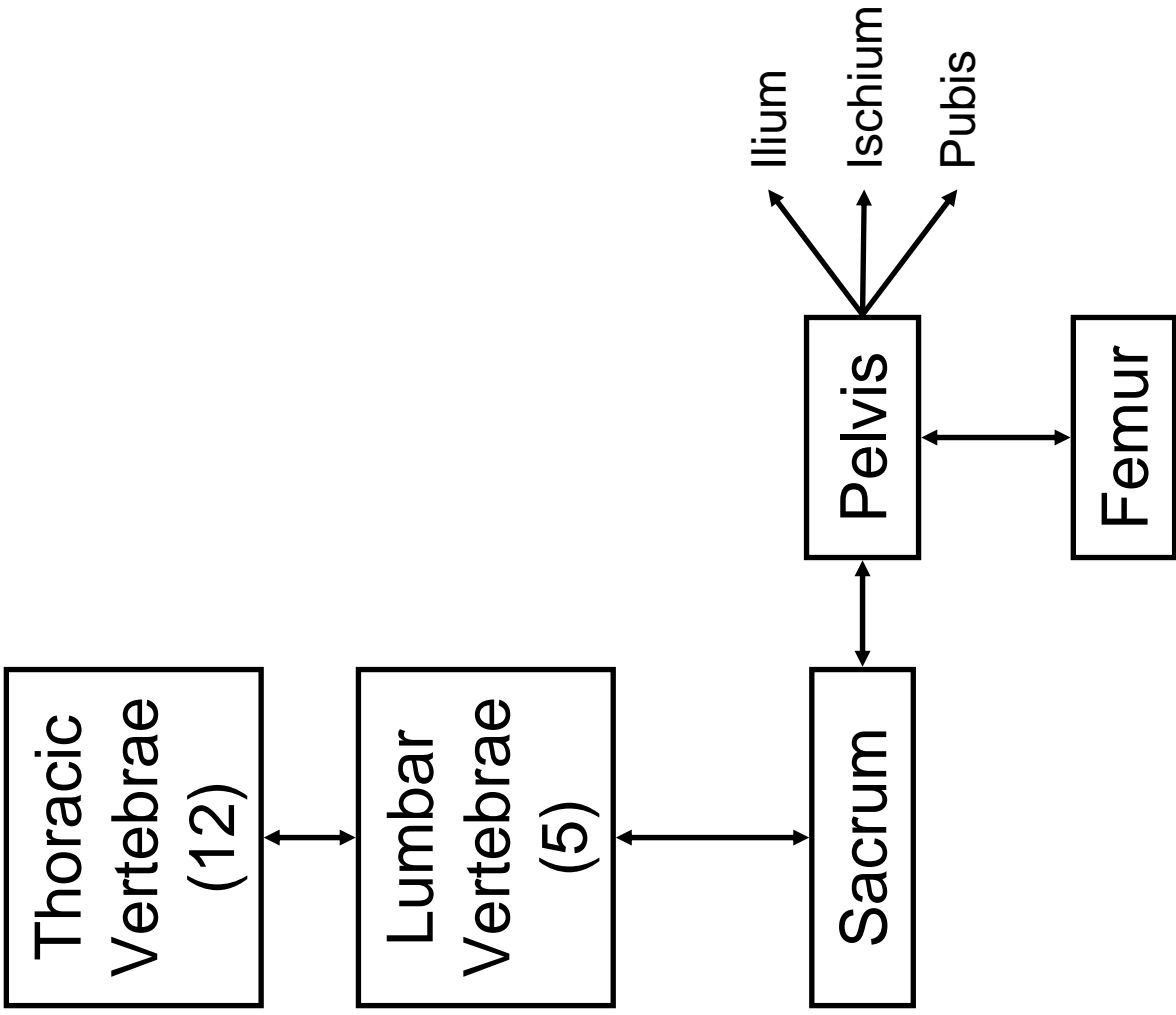
Popliteal

Hip, Pelvis

&

Low Back



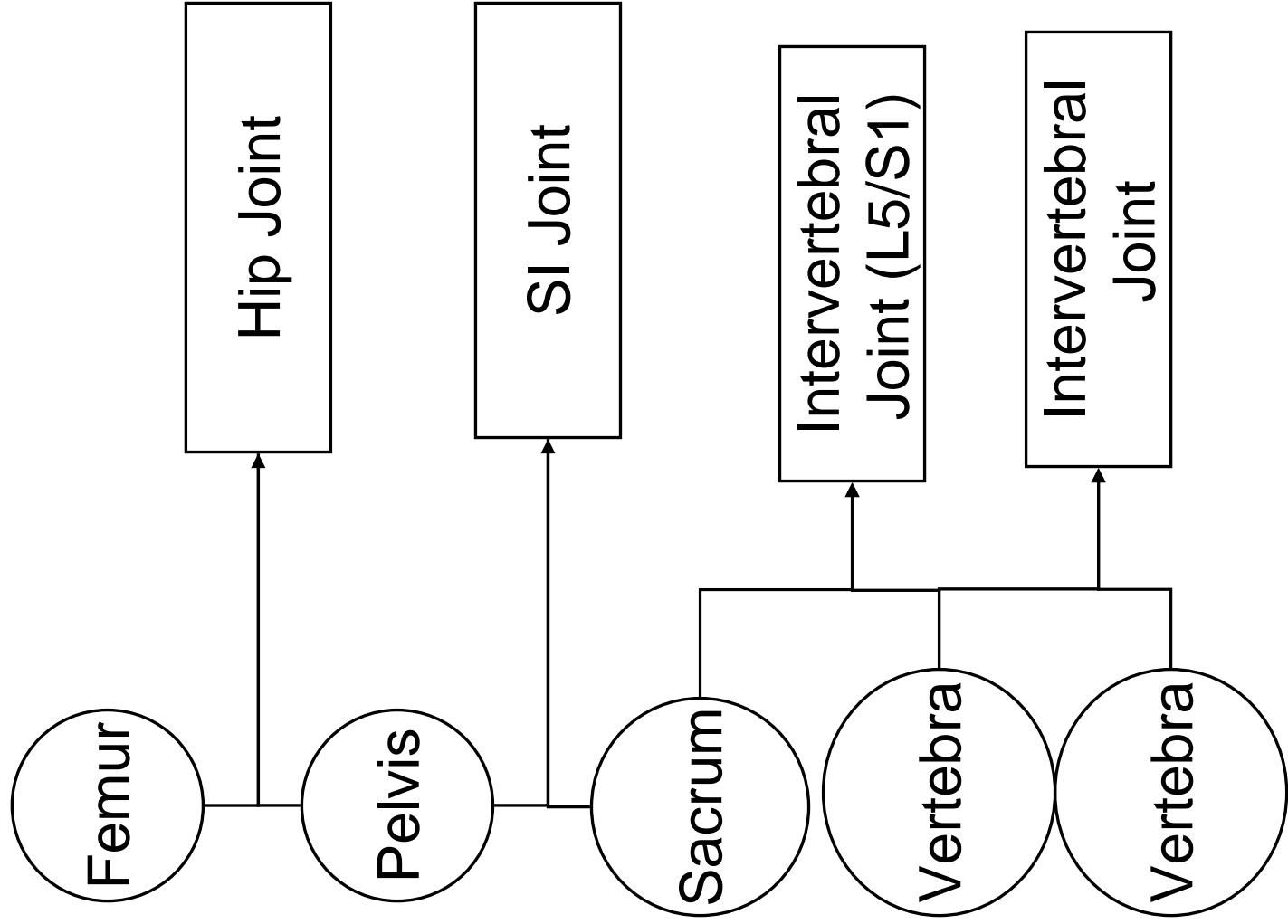


# Femoral Neck

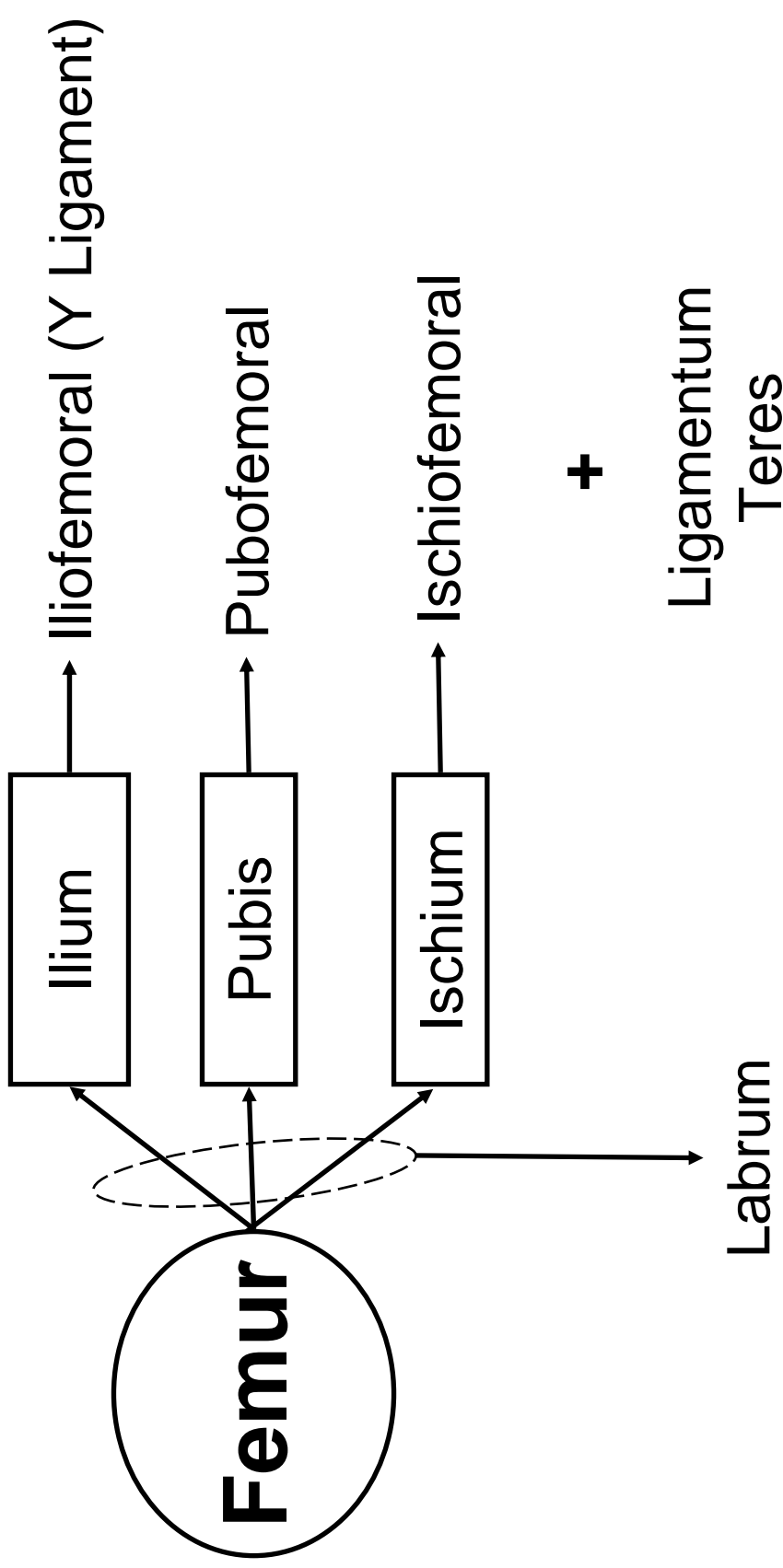
	Normal	Increased	Decreased
Angle of Inclination			
Angle of Torsion			

## **Important Parts of the Vertebrae**

- Vertebral Body
- End Plate
- Foramen
  - Vertebral
  - Intervertebral
- Neural Arch
  - Pedicle, Lamina, Pars Interarticularis
- Intervertebral Disc
  - Annulus Fibrosus
  - Nucleus Pulposus



# Hip: 3 Bones, 3 Ligaments



# Hip Ligaments

Ligament	Connects	Restrains
Ilofemoral		
Pubofemoral		
Ischiofemoral		
Ligamentum Teres		

## **SI Joint Ligaments**

- Sacroiliac Ligaments
  - Iliac crest to tubercles of 1st 4 sacral vertebrae
- Sacrotuberous Ligament
  - Ischial tuberosities to lat border of sacrum
- Sacrospinous Ligament
  - Ischial spines to lat border of sacrum

# Spine Ligaments

**Anterior  
Longitudinal  
Ligament**

**Body**

**Posterior  
Longitudinal  
Ligament**

**Ligamentum  
Flavum**

**Supra-  
Spinous  
Ligament**

**Spinous  
Process**

**Inter-  
Spinous  
Ligament**

**Inter-  
Transverse  
Ligament**




# Spine Ligaments

Ligament	Connects		Restrains
ALL			
PLL			
Ligamentum Flavum			
Supraspinous Ligament			
Interspinous Ligament			
Intertransverse Ligament			

# Hip Joint

*Flex*

Anterior



Lateral

Medial

*Abduct*

*Adduct*  
*IR*


Posterior

*Extend*  
*ER*

# Hip Joint

Rectus Femoris  
Sartorius  
Psoas Major  
Psoas Minor  
Iliacus

Pectineus  
Adductor Brevis  
Adductor Longus  
Adductor Magnus  
Gracilis



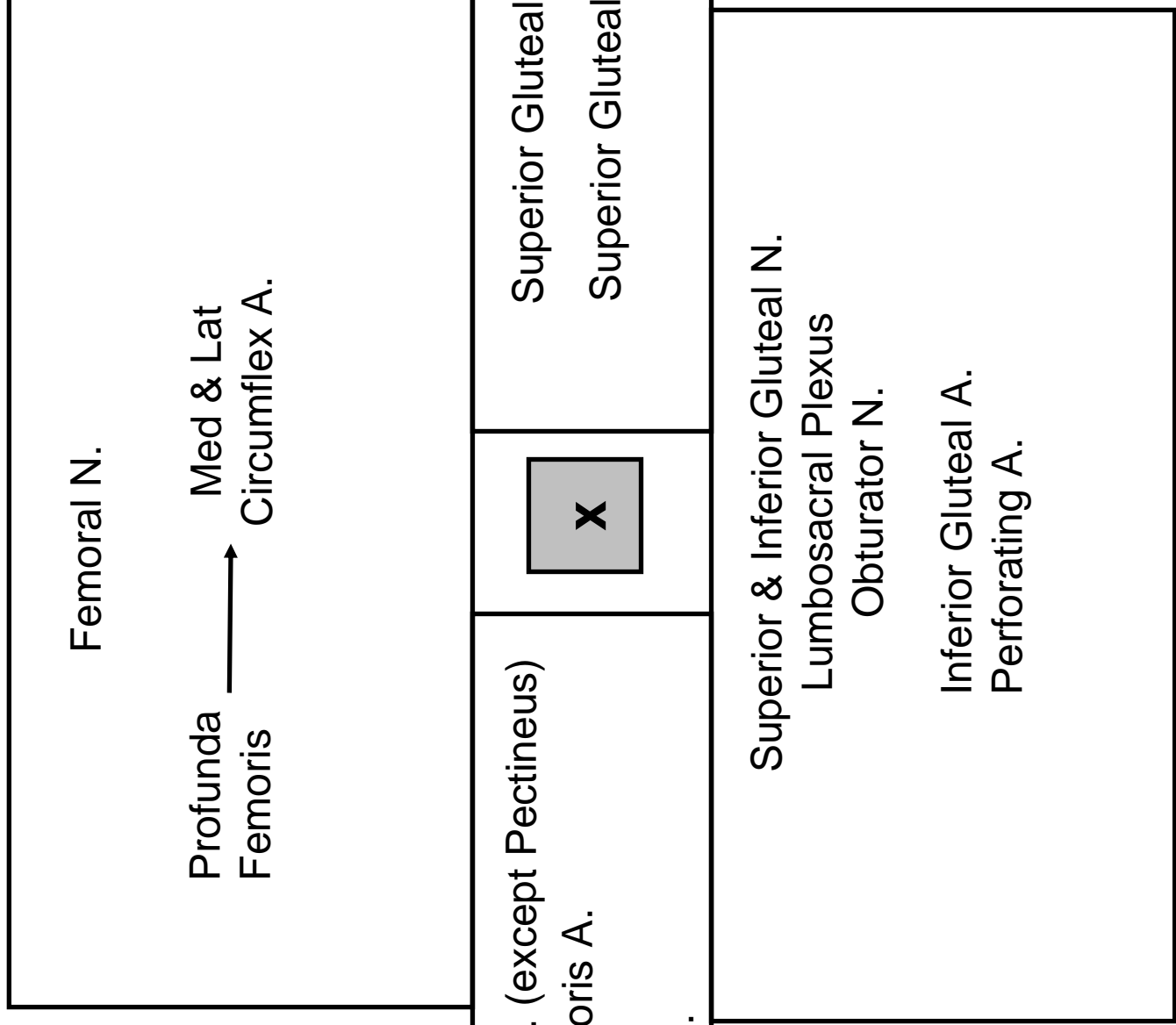
TFL  
Gluteus Medius  
Gluteus Minimus

Glute Max  
Hamstrings  
Adductor Magnus  
Piriformis  
Gemellus Superior  
Obturator Internus  
Gemellus Inferior  
Obturator Externus  
Quadratus Femoris


# Hip Muscle – Joint Interaction

Motion	Prime Mover(s)
Flexion	
Extension	
IR	
ER	
Abduction	
Adduction	


# Hip Joint



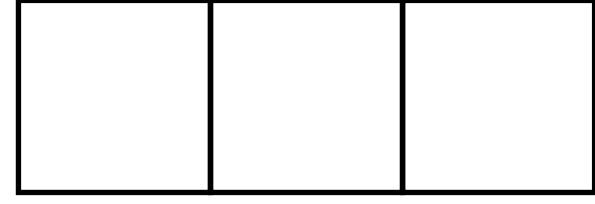# SI Joint Movements



Anterior




**Nutation**



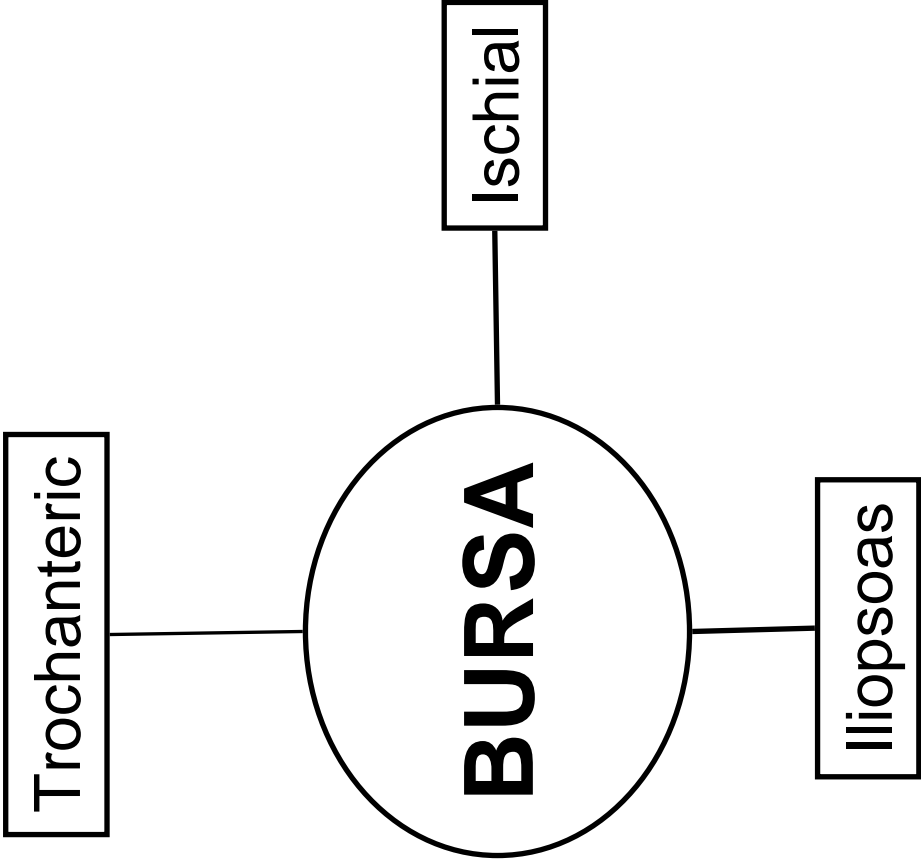
Posterior

**Counter-  
Nutation**

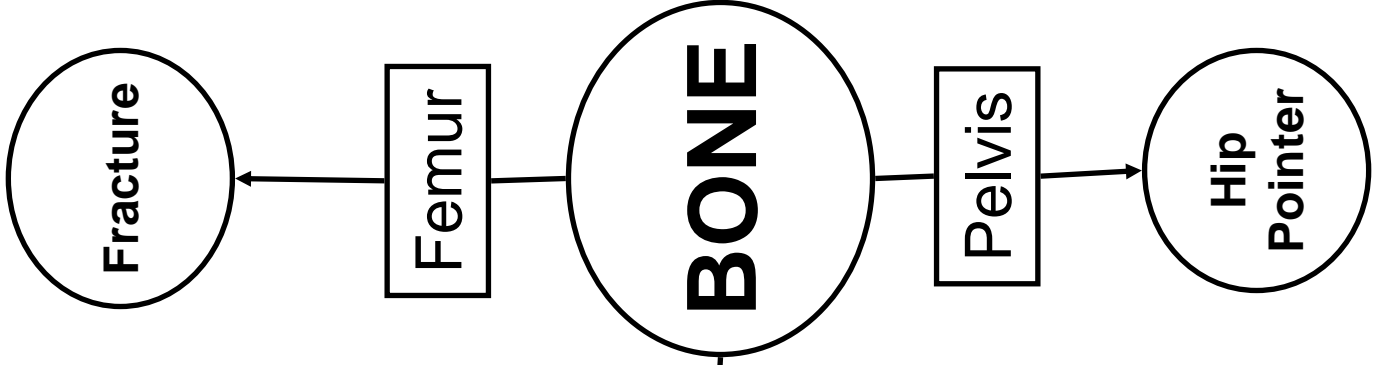


# Spine Muscle – Joint Interaction

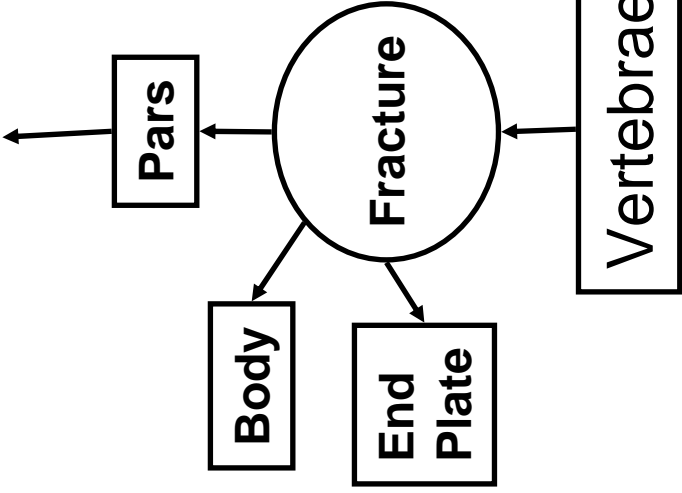
Motion	Prime Mover(s)
Flexion	
Extension	
Rotation	
Lateral Flexion	

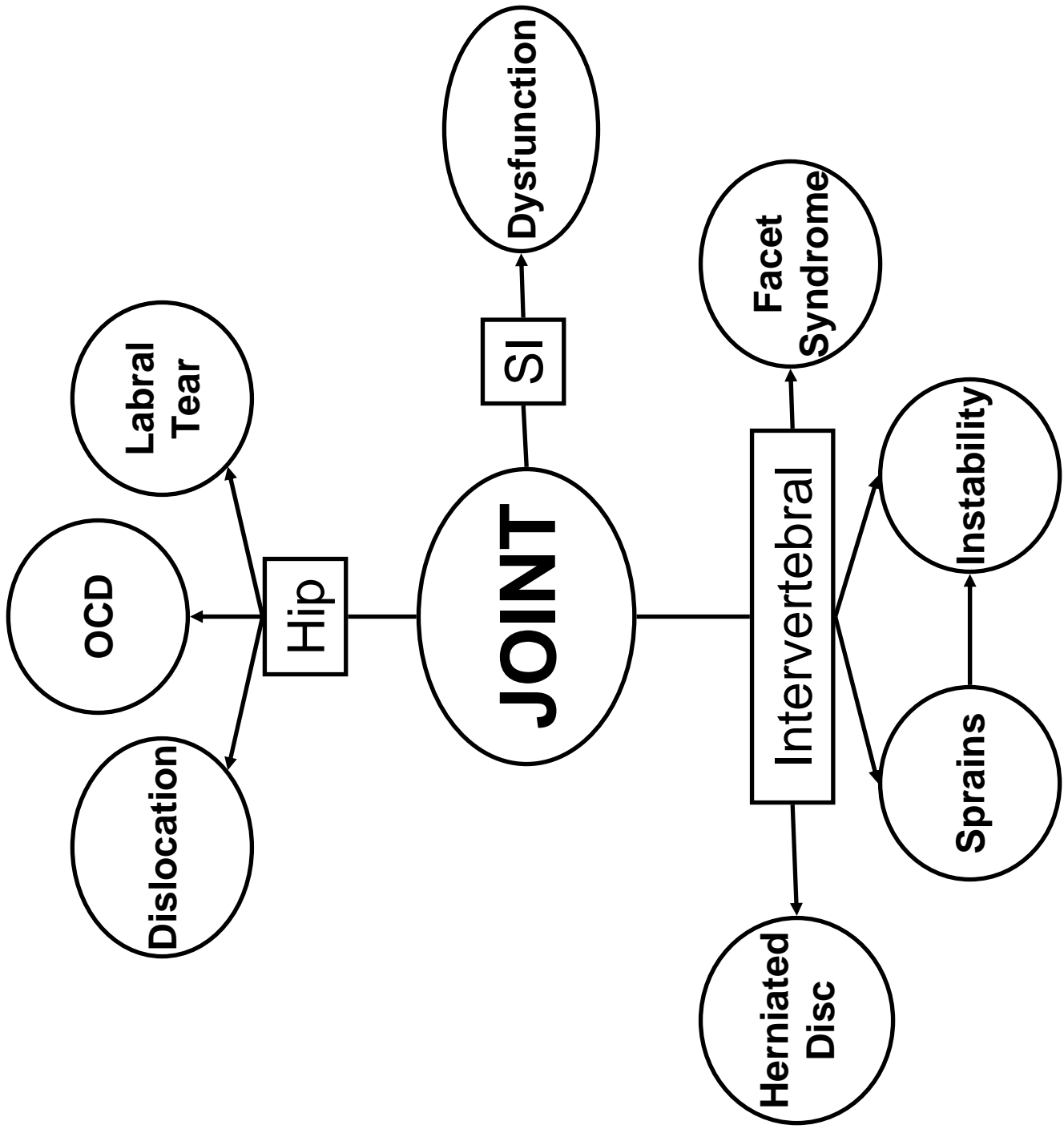


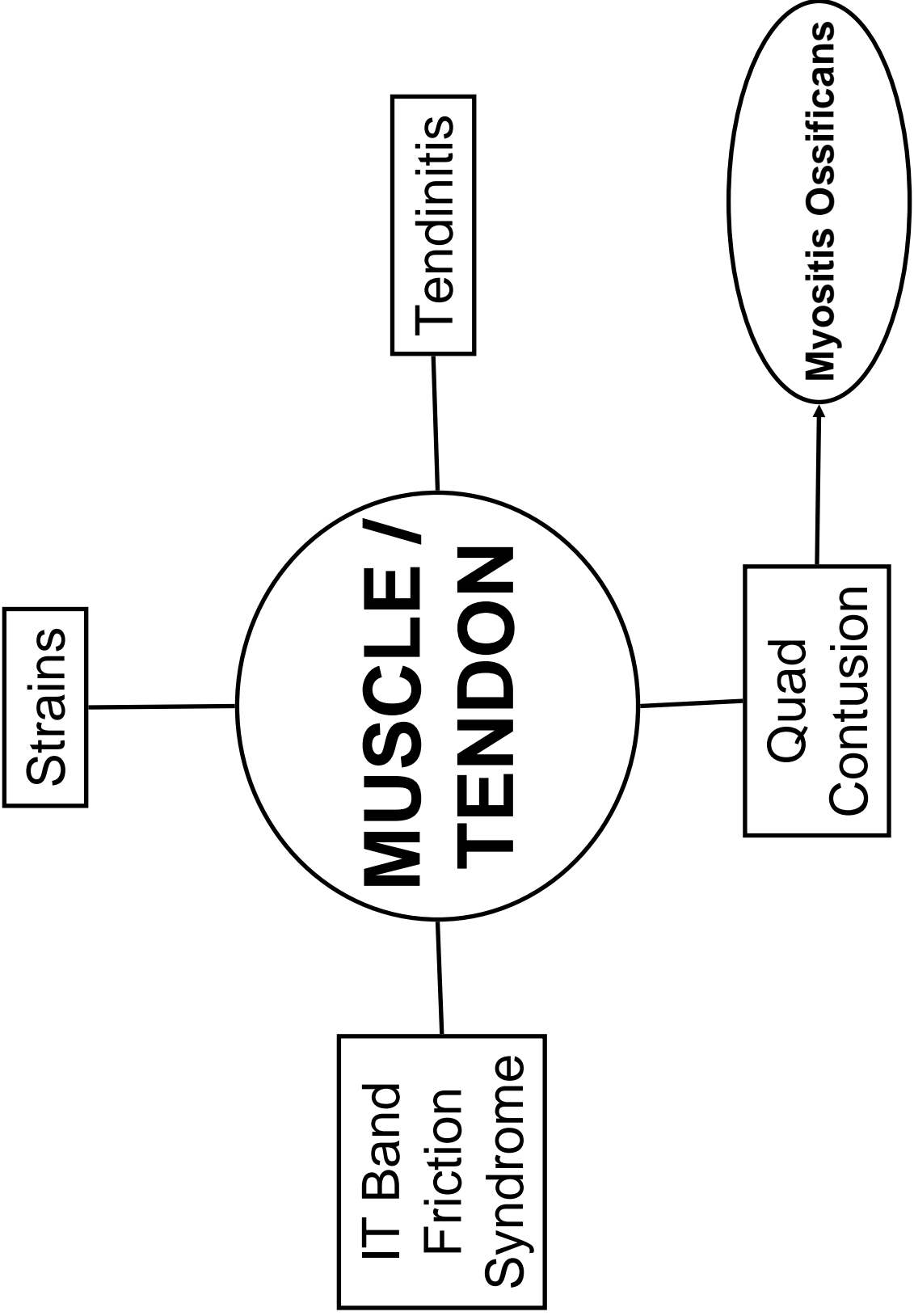




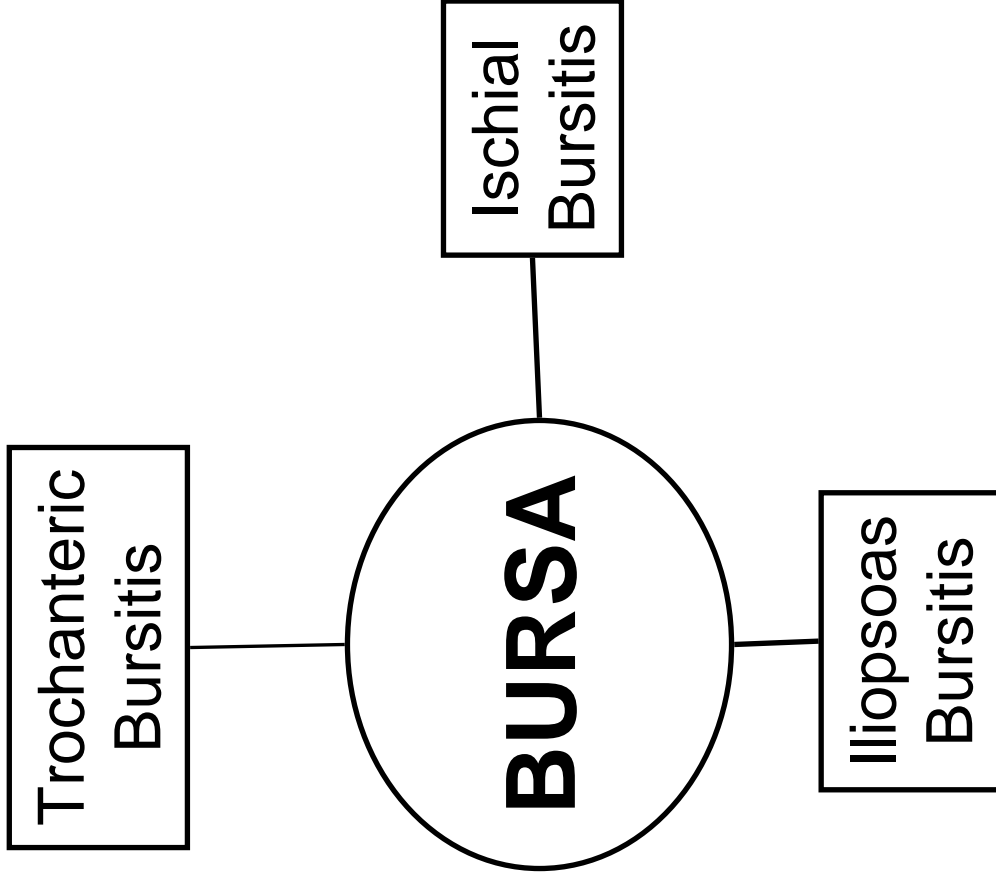
*Spondylolisthesis ← Spondylolysis*

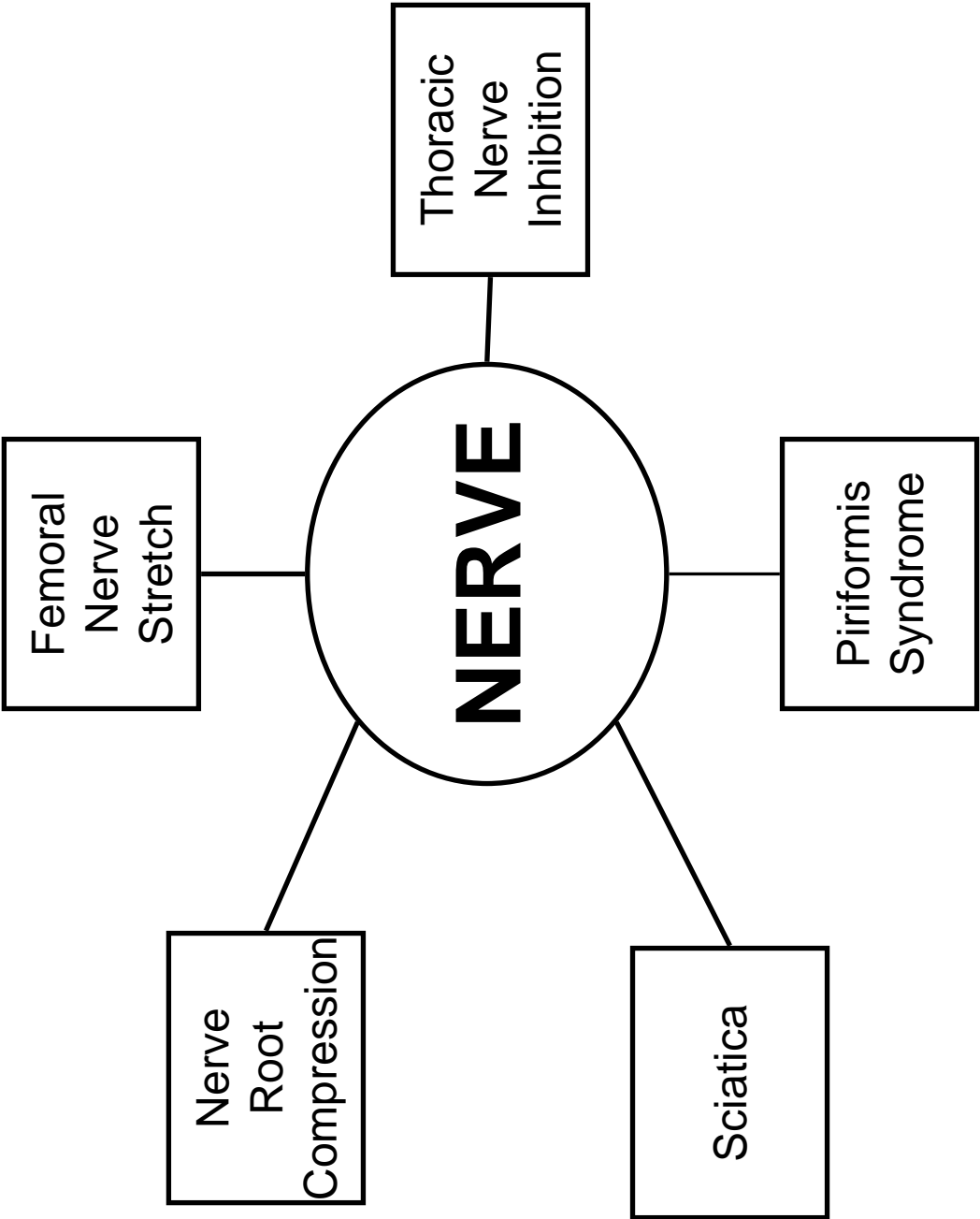


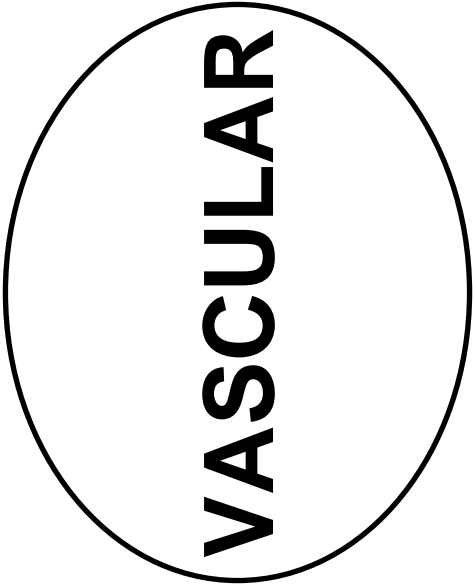




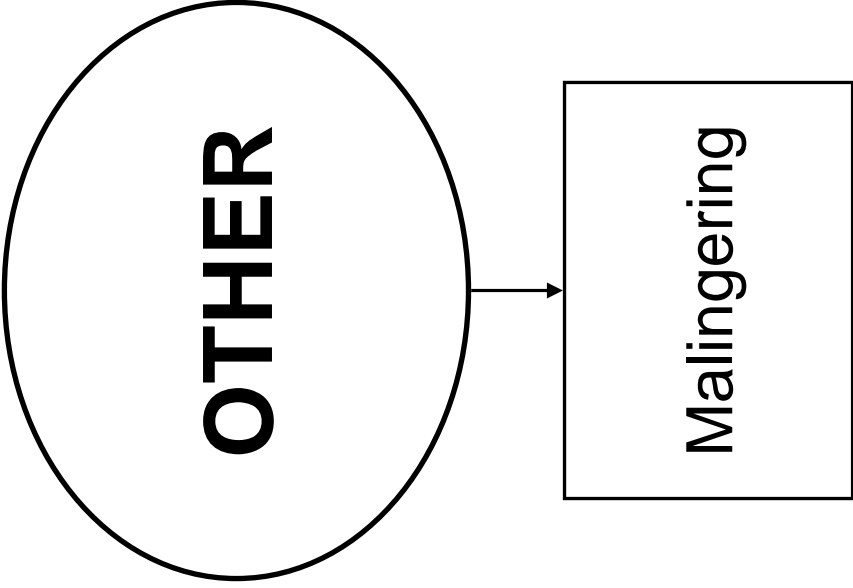
***“Snapping Hip”***

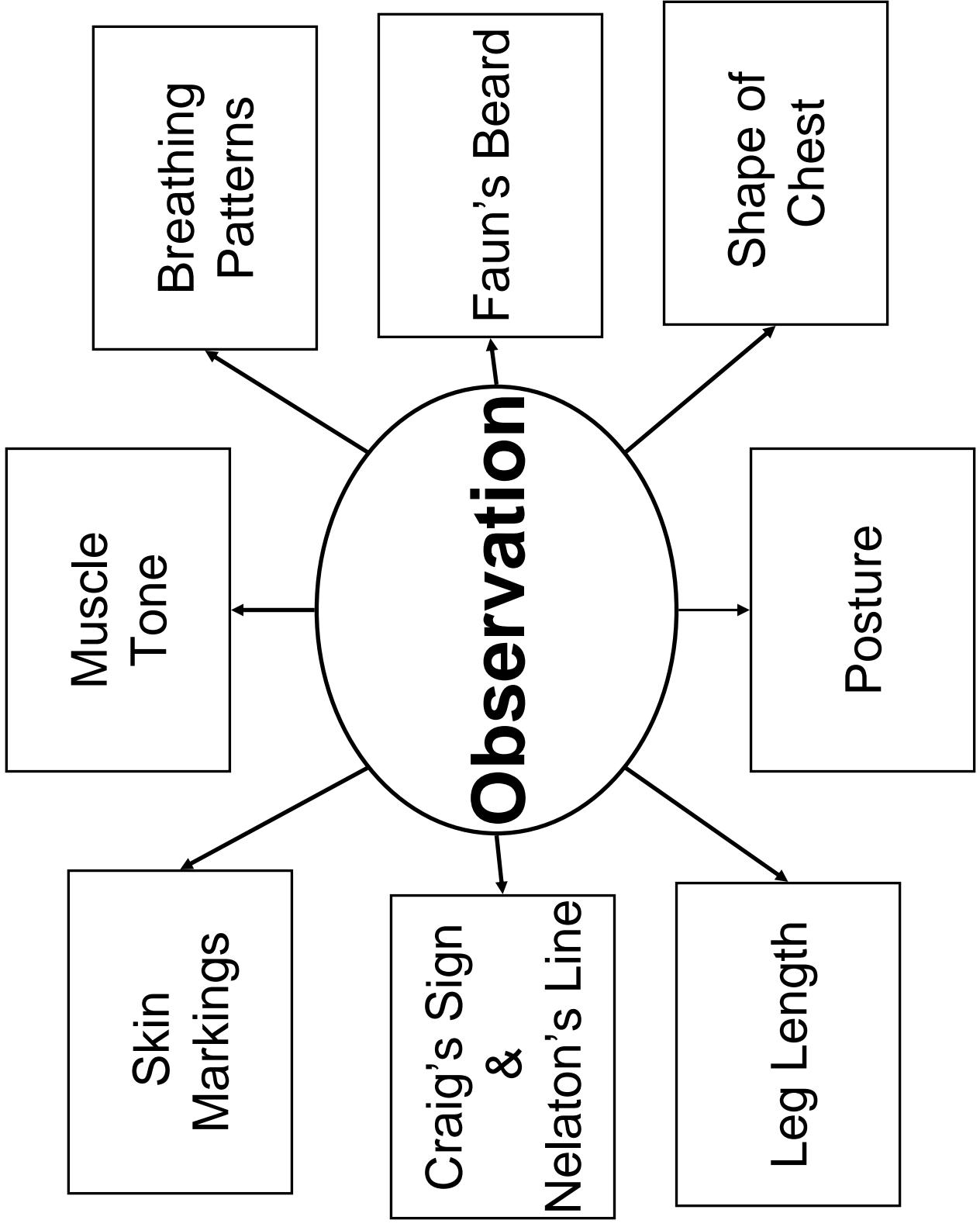






**VASCULAR**







## Hip, Pelvis, & Low Back Palpation Guide

### Medial Structures

Pubic Bone

Gracilis  
Adductor Longus  
Adductor Magnus  
Adductor Brevis

### Anterior Structures

ASIS

Sartorius  
Rectus Femoris  
Femoral Artery

AIS

### Lateral Structures

Iliac Crest

Tensor Fascia Latae  
IT Band  
Gluteus Medius

Greater Trochanter

### Posterior Structures

PSIS

Gluteus Maximus

Ischial Tuberosity

Hamstring Muscle  
Group  
Sciatic Nerve

Median Sacral  
Crests

### Lumbar Spine

Spinous Processes

Supraspinous  
Ligaments

Erector Spinae  
Latissimus Dorsi  
External Obliques  
Rectus Abdominis

Thoracic Spine

Spinous Processes

Supraspinous  
Ligaments

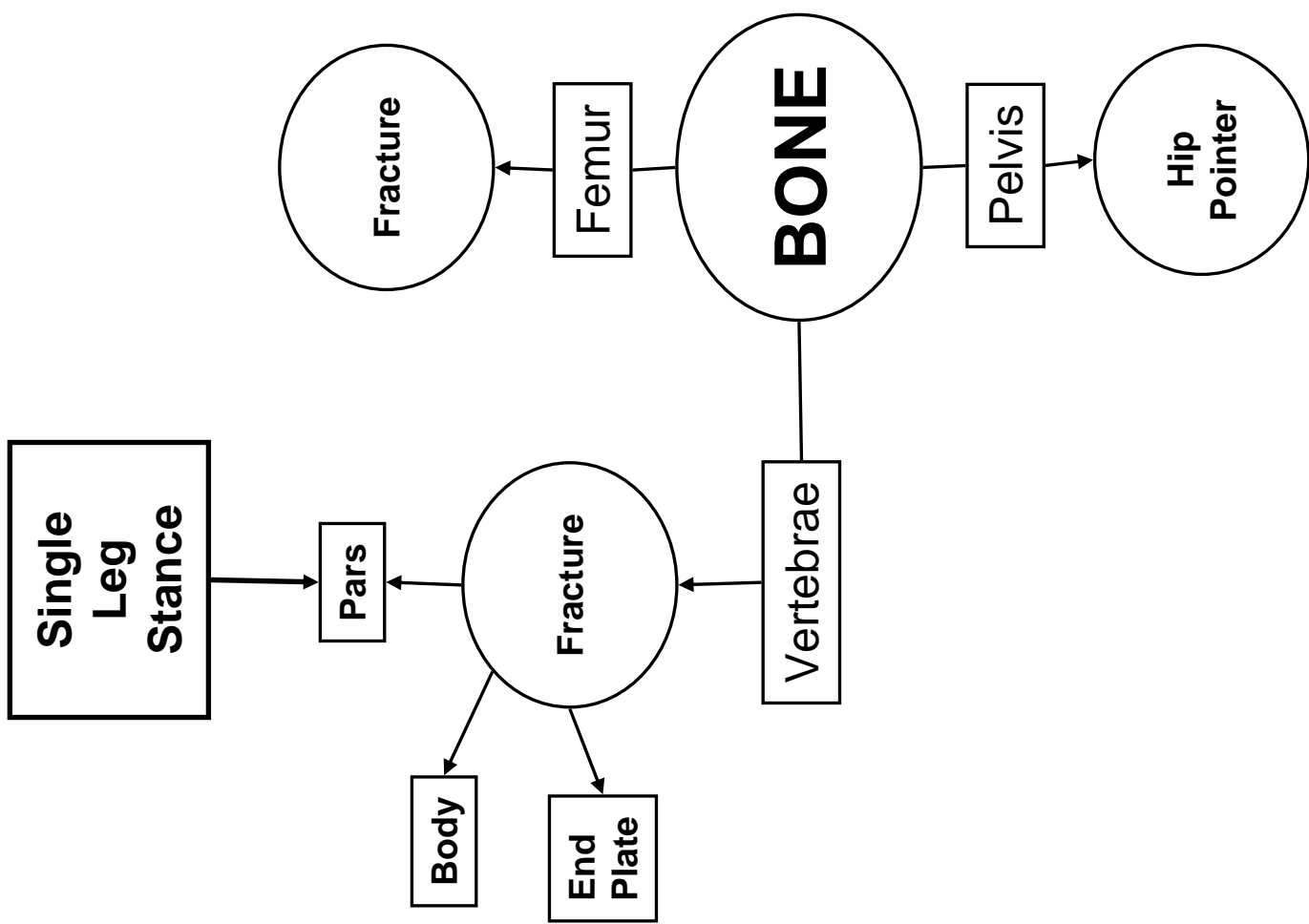
Costovertebral Junction

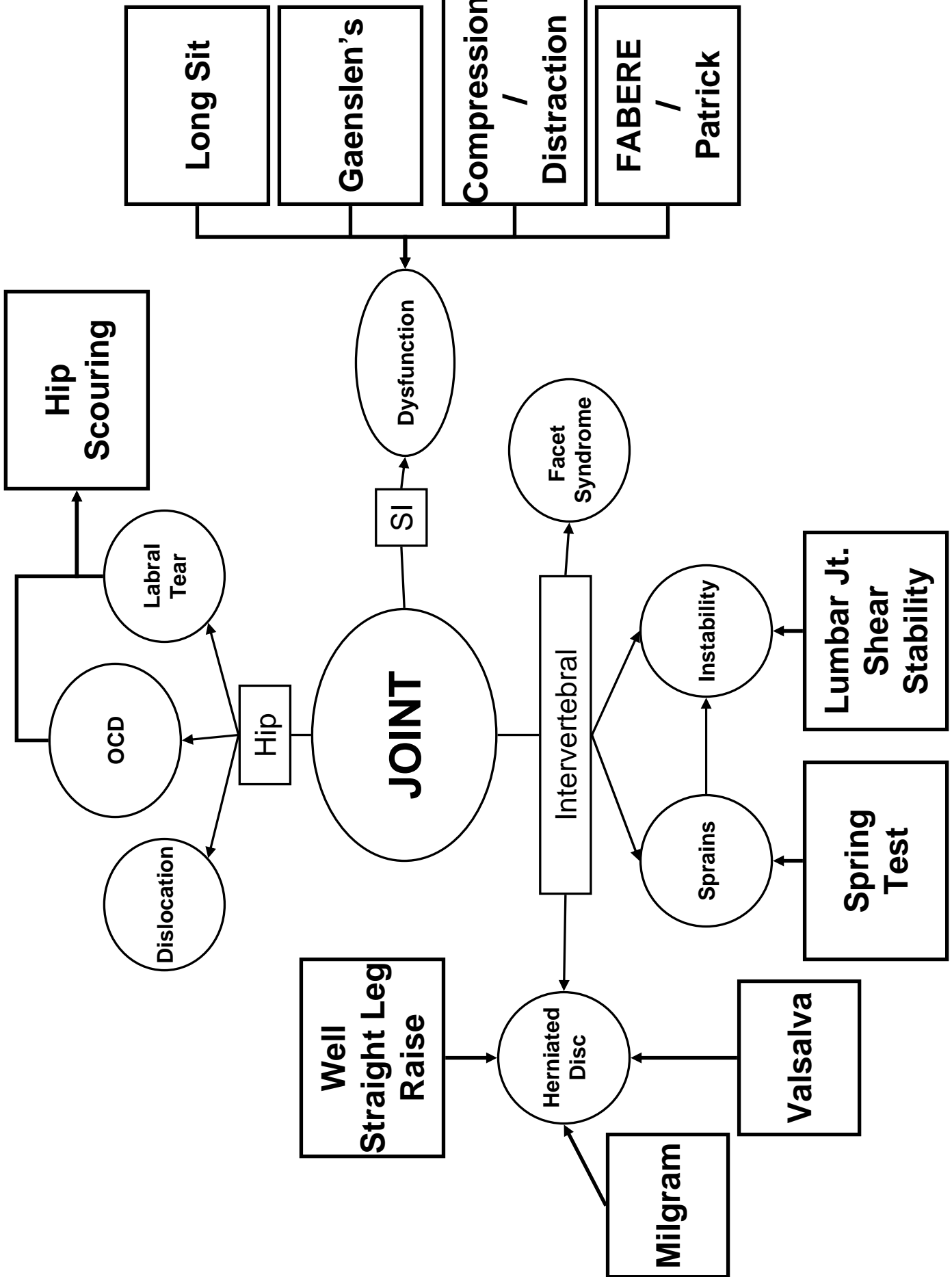
Trapezius

Erector Spinae

<b>Structure</b>	<b>Landmark</b>
C1	TPs are one finger's breadth inferior to mastoid process
C3-4	Posterior to hyoid bone
C4-5	Posterior to thyroid cartilage
C6	Posterior to cricoid cartilage; moves during flexion and extension
C7	Prominent spinous process
T1	Prominent below C-spine, doesn't move with flexion/extension of C-spine
T2	Posterior from jugular notch
T3	Even with medial border of scapular spine
T7	Even with inferior angle of scapula
L3	Posterior to umbilicus
L4	Level with the iliac crest
L5	Bilateral dimples
S2	PSIS

<b>Level</b>	<b>Spinous process is....</b>
Cervical	Even with vertebral body
T 1-3	Even with TP
T 4-6	Midway between its TP and the TP of the vertebra below it
T 7-9	Even with the TP of the inferior vertebra
T 10	Even with the TP of T 11
T 11	Halfway between T 11 and T 12
T 12	Even with the vertebral body of T 12
Lumbar	Even with the inferior half of the vertebral body





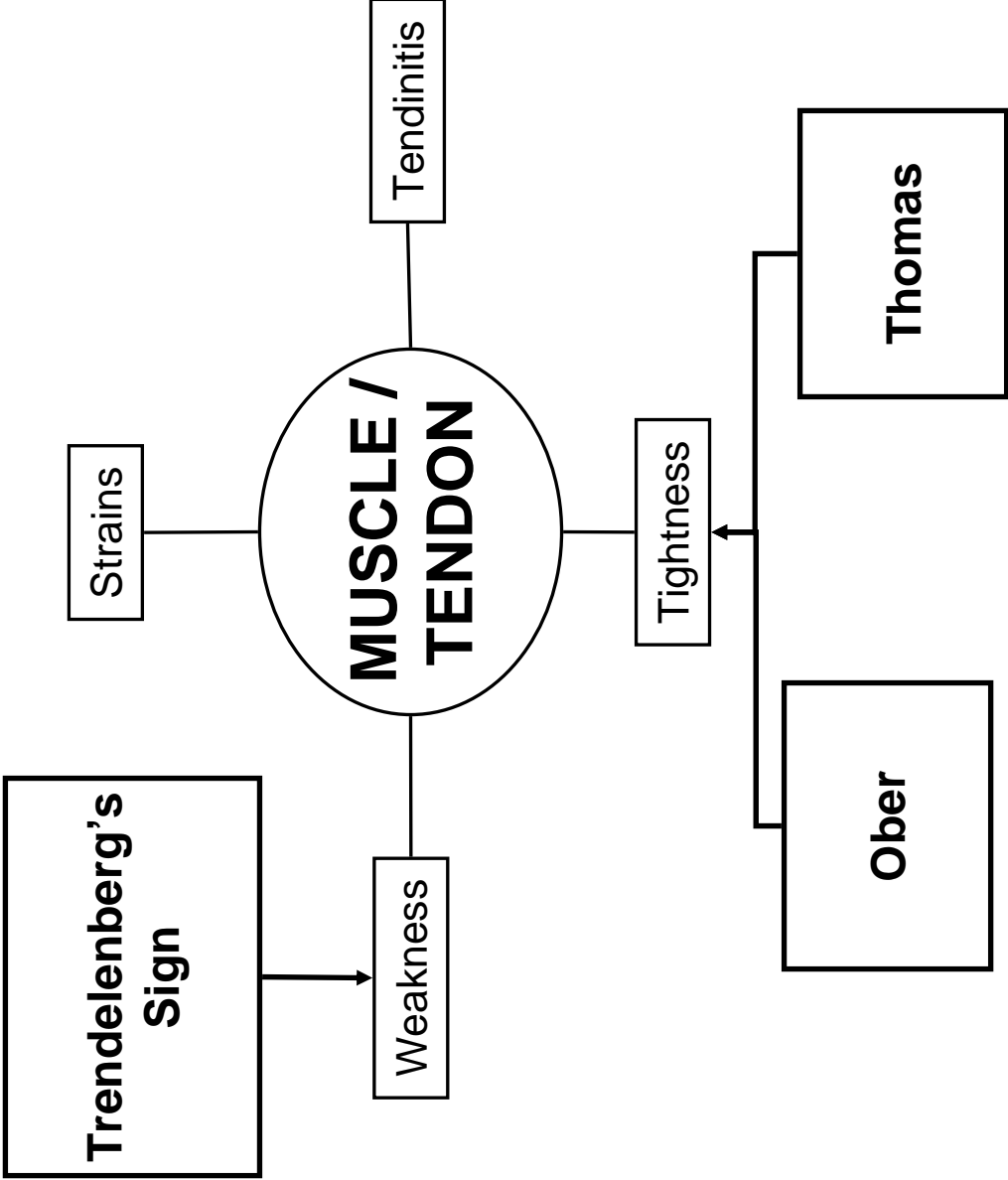
# Goniometry - Hip

Motion	Normal ROM	Stationary Arm	Axis of Rotation	Moving Arm
Flexion				
Extension				
IR				
ER				
Abduction				
Adduction				

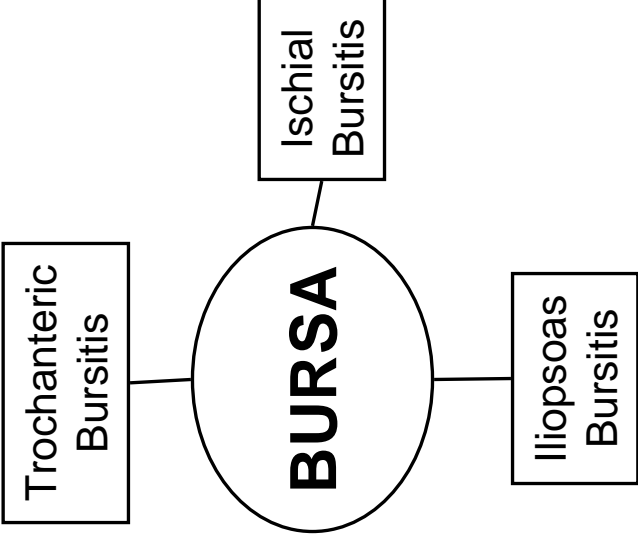
# Goniometry - Spine

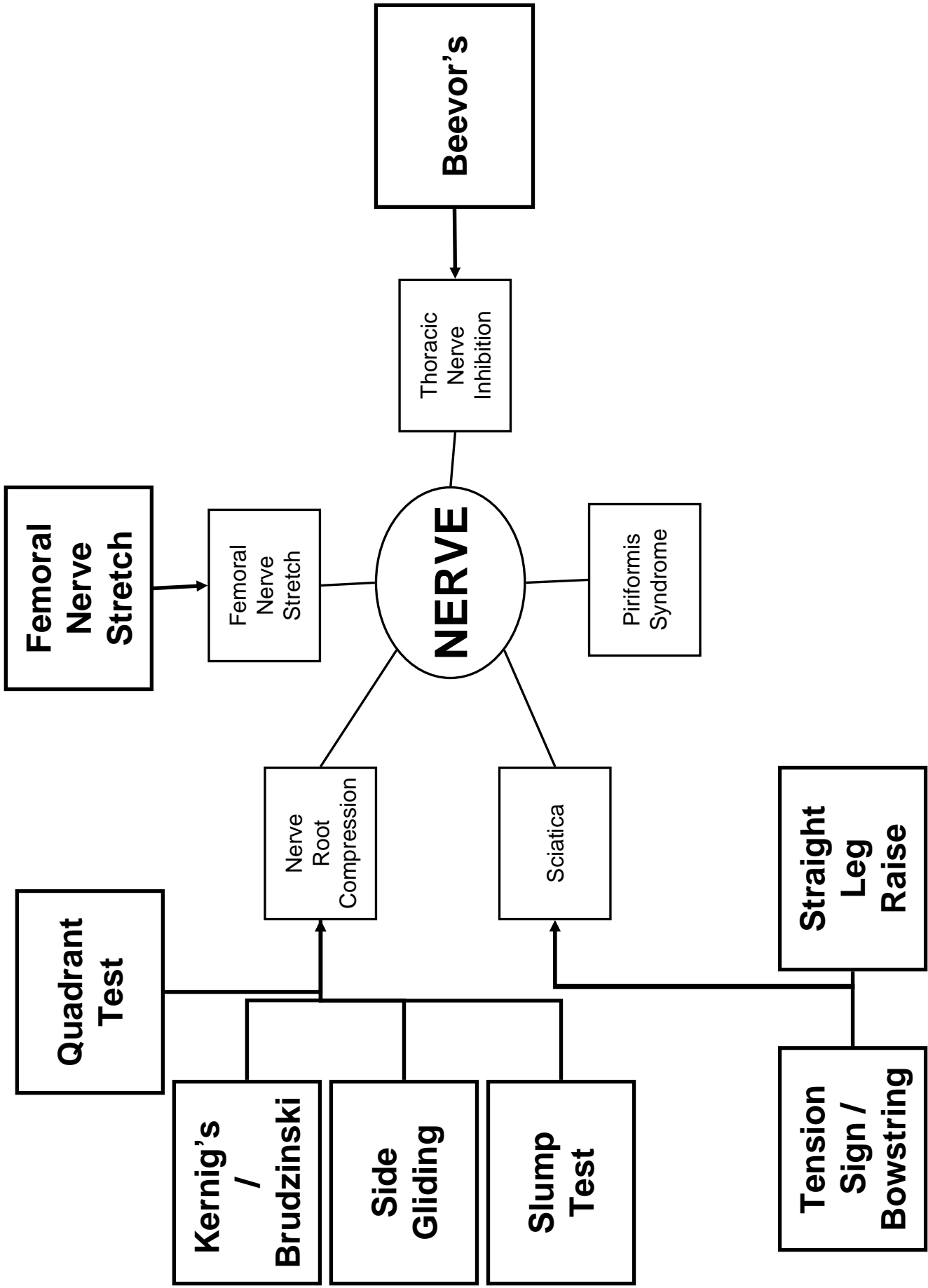
Motion	Normal ROM	Stationary Arm	Axis of Rotation	Moving Arm
Flexion				
Extension				
Rotation				
Lateral Flexion				

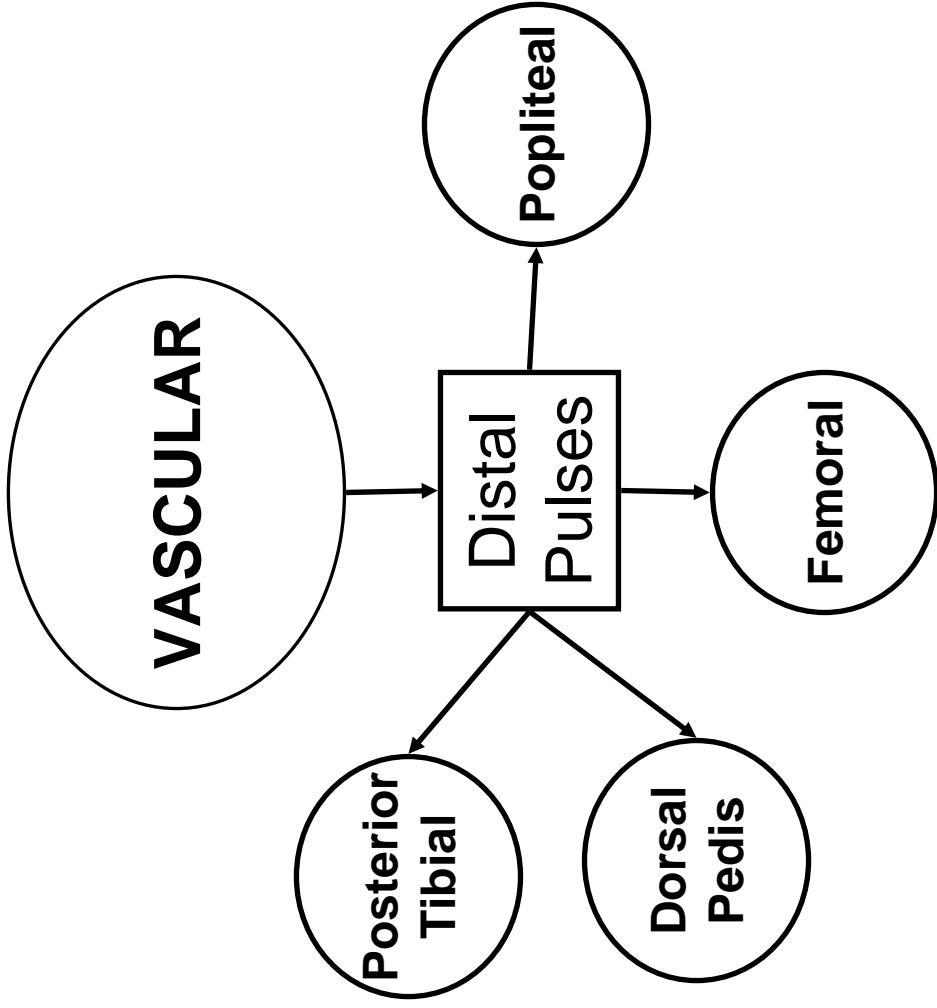


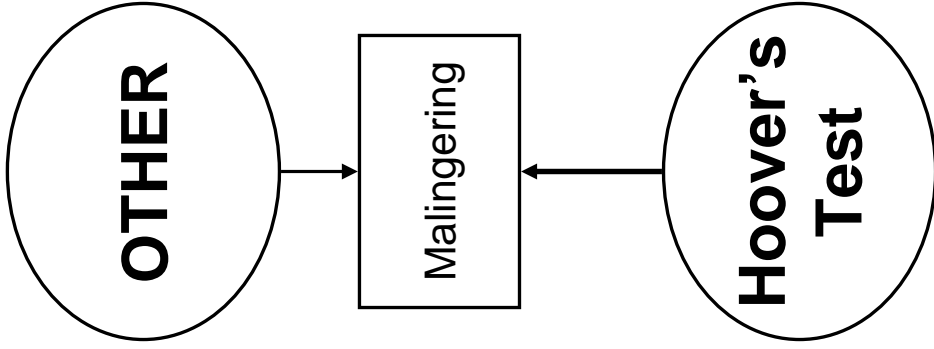


	PROM	AROM
Rectus Femoris	KNEE	KNEE
	HIP	HIP
Hamstrings		









**Kinesiology 338L**  
**Hip, Pelvis and Low Back Checklist**

History \_\_\_\_\_

General History

Specific to this Region

Observation \_\_\_\_\_

General Inspection

Skin Markings

Faun's Beard

Muscle Tone

Breathing Patterns

Shape of Chest

Posture

Craig's Sign

Nelaton's Line

Palpation

Medial Structures \_\_\_\_\_

Pubic Bone

Gracilis

Adductor Longus

Adductor Magnus

Adductor Brevis

Anterior Structures

---

ASIS

Sartorius

Rectus Femoris

Femoral Artery

AIIS

Lateral Structures

---

Iliac Crest

Tensor Fascia Latae

IT Band

Gluteus Medius

Greater Trochanter

Posterior Structures

---

PSIS

Gluteus Maximus

Ischial Tuberosity

Hamstring Muscle Group

Sciatic Nerve

Median Sacral Crests

Lumbar Spine

---

Spinous Processes

Supraspinous Ligaments

Erector Spinae

Latissimus Dorsi

External Obliques

Rectus Abdominis



Thoracic Spine

---

Spinous Processes

Supraspinous Ligaments

Costovertebral Junction

Trapezius

Erector Spinae

Stress

Bone

---

Single Leg Stance

Joint

PROM

---

Hip: Flex/Ext

Hip: ER/IR

Hip: Abd/Add

Spine: Flex/Ext

Spine: Lat Flexion

Spine: Rotation

Special Tests

---

Hip Scouring

Long Sit

Gaenslen's

SI Compression / Distraction

FABERE / Patrick

Lumbar Jt. Shear Stability

- Spring Test
- Valsalva
- Milgram
- Well Straight Leg Raise

Muscle/Tendon

---

A/P/RRROM

---

- Hip: Flex/Ext
- Hip: ER/IR
- Hip: Abd/Add
- Spine: Flex/Ext
- Spine: Lat Flexion
- Spine: Rotation

Special Tests

---

- Thomas Test
- Ober's Test
- Trendelenberg Sign

Nerve

Neurological Screen

---

Special Tests

---

- Beevor's
- Femoral Nerve Stretch
- Quadrant Test
- Kernig's Brudzinski
- Side Gliding
- Slump Test

Tension Sign/Bowstring

Straight Leg Raise

Vascular

Distal Pulses

Dorsal Pedis A.

Post Tib A.

Popliteal A.

Femoral A.

Other

Hoover's

---

---